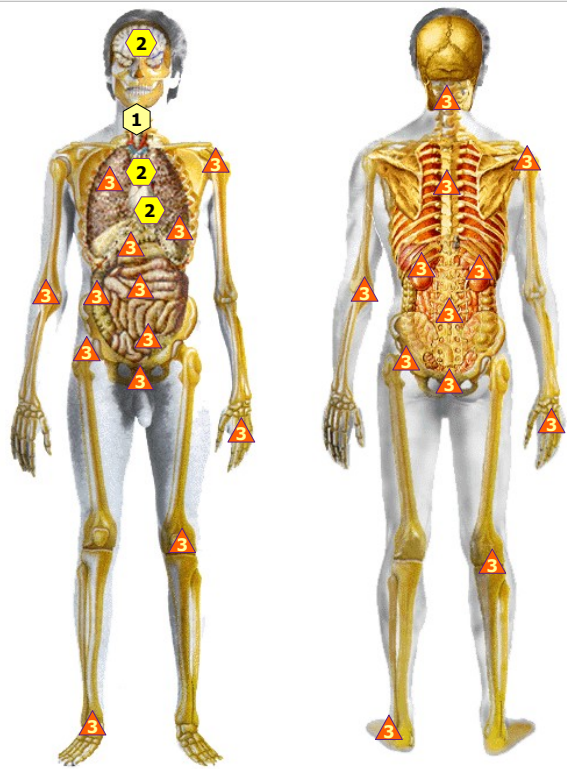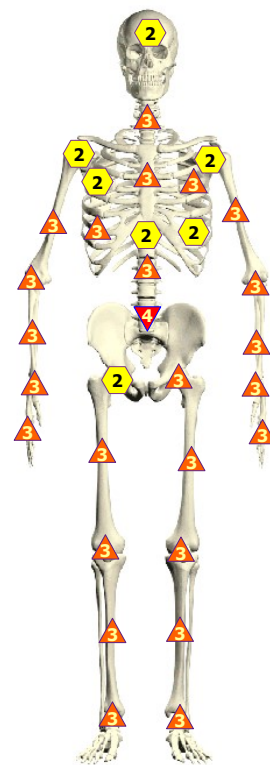
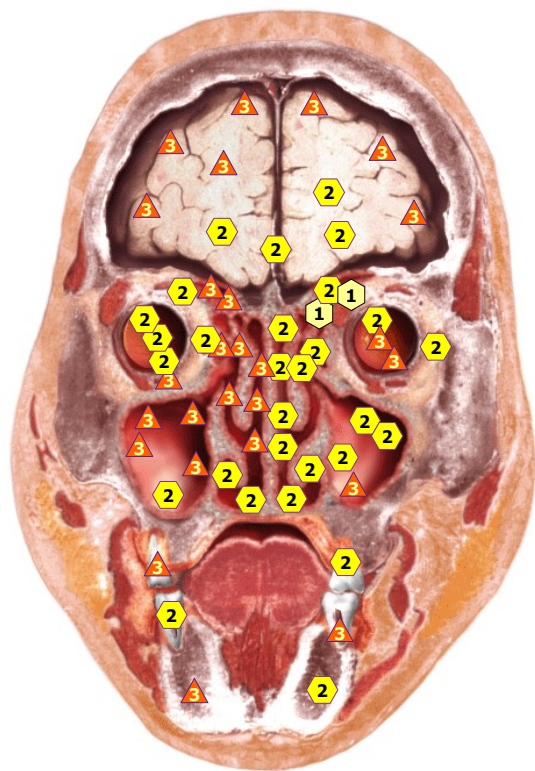


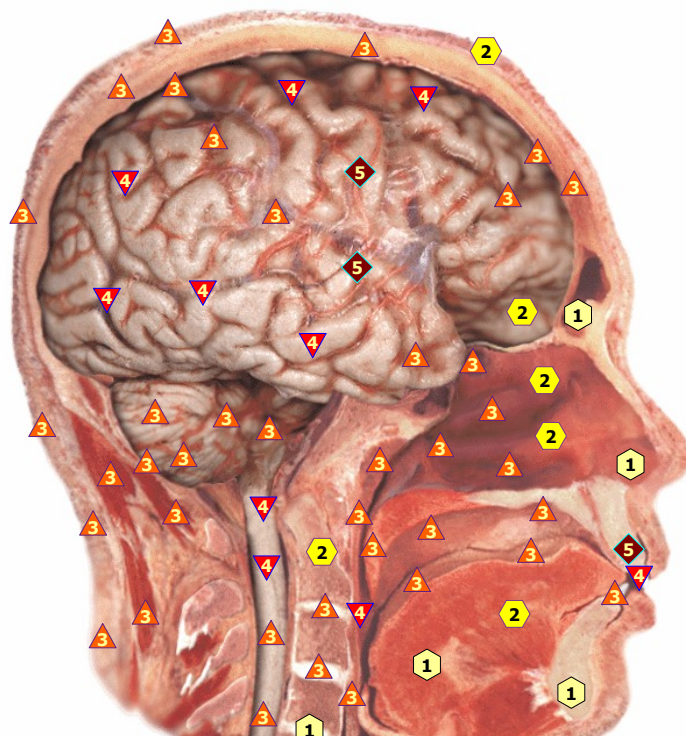
11/09/2024 BODY OF MAN



11/09/2024 SKELETON front



11/09/2024 FRONTAL CROSS-SECTION OF HEAD



11/09/2024 LONGITUDINAL CROSS-SECTION OF HEAD



The level of latent dynamic activity



Removing of the characteristics upon the higher level; the state of regulating systems' straining



Compensated breaches of adaptation mechanisms



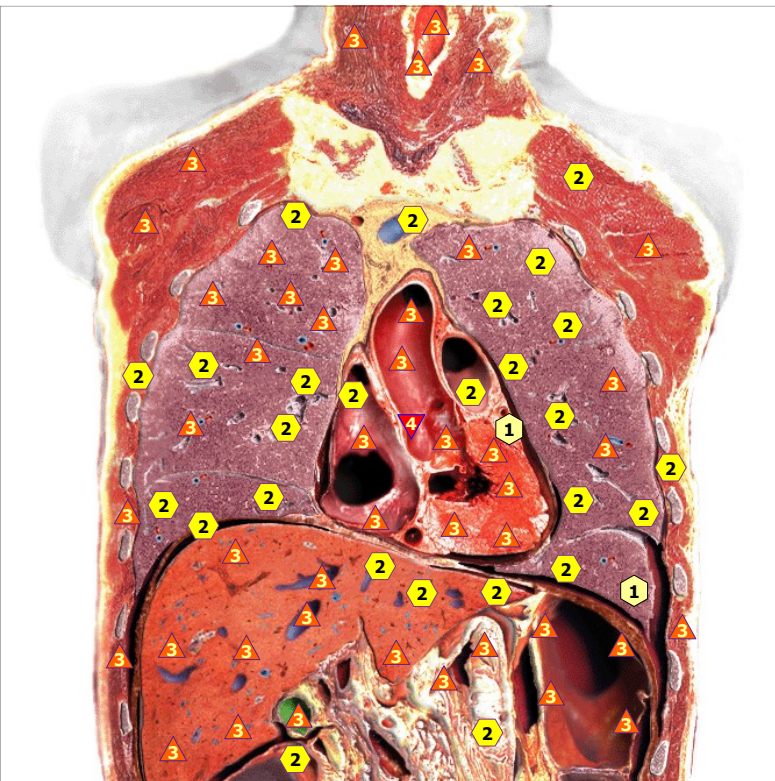
The level of the optimum regulation



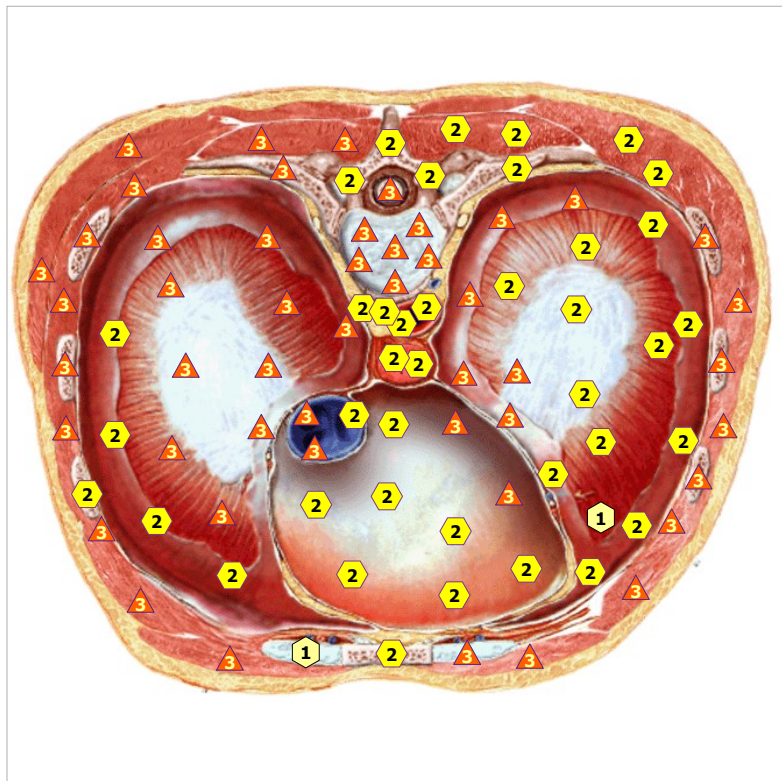
Asthenisation of regulation mechanisms



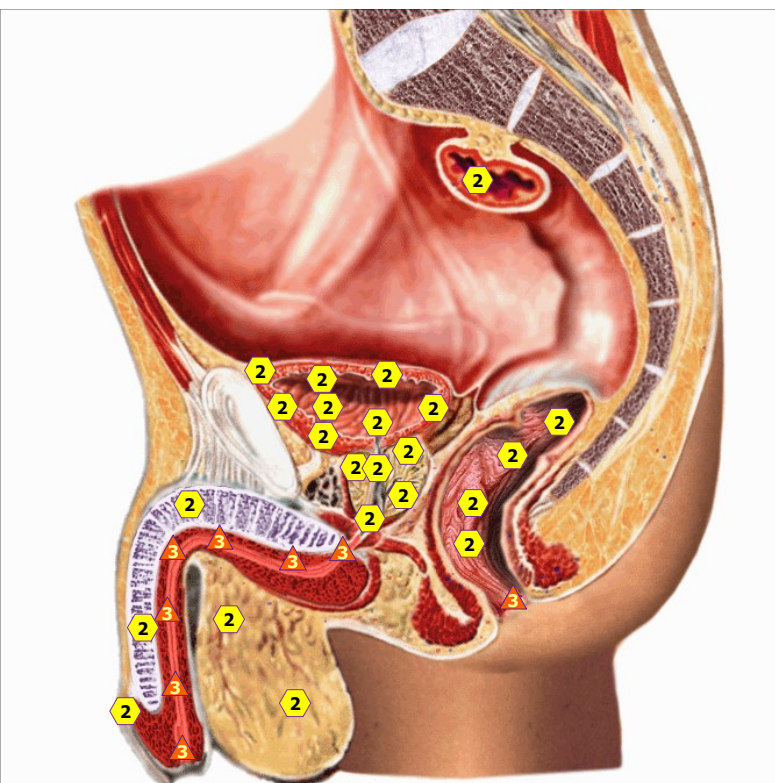
Decompensation of adaptation mechanisms; expressed pathological states



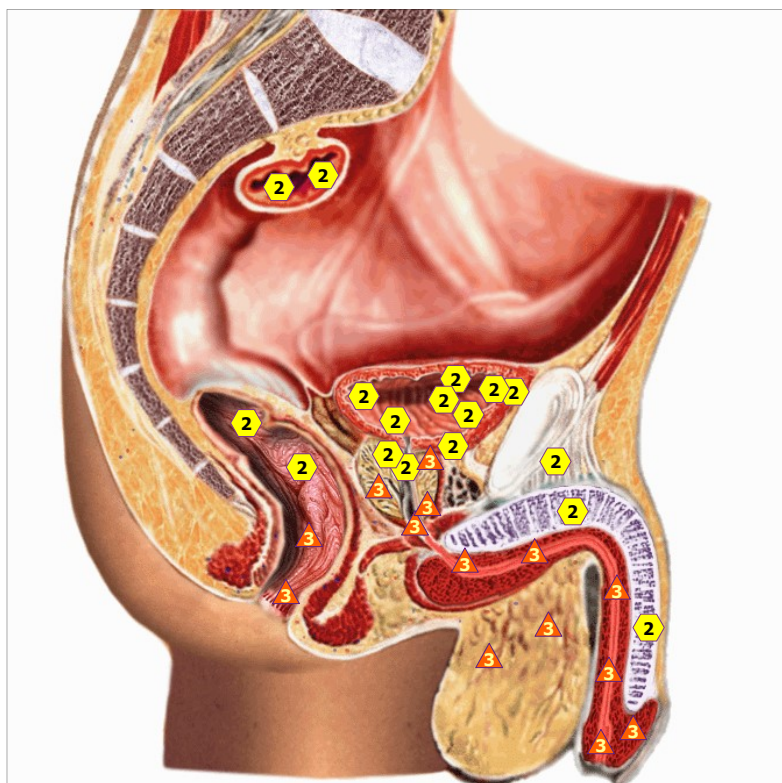
11/09/2024 CORONAL THORACOTOMY AT THE LEVEL OF ASCENDING PART OF AORTA, FRONT VIEW



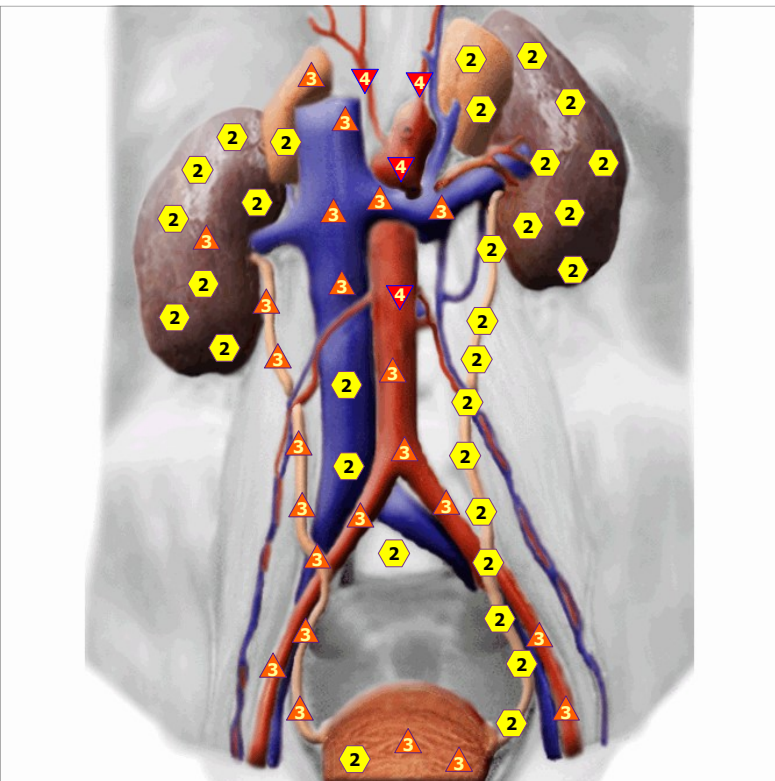
11/09/2024 midriff



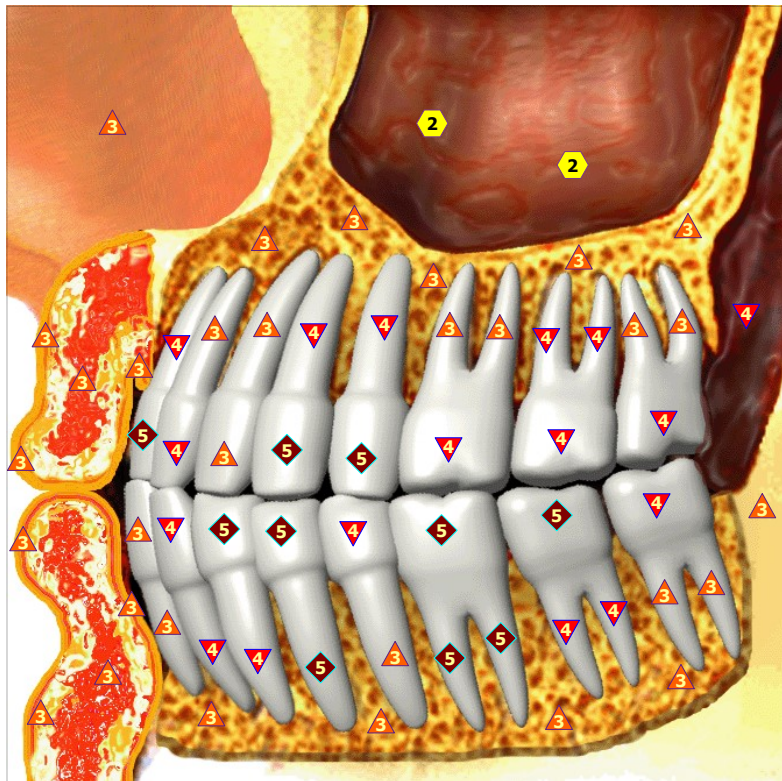
11/09/2024 ORGANS OF MALE SMALL PELVIS, right side



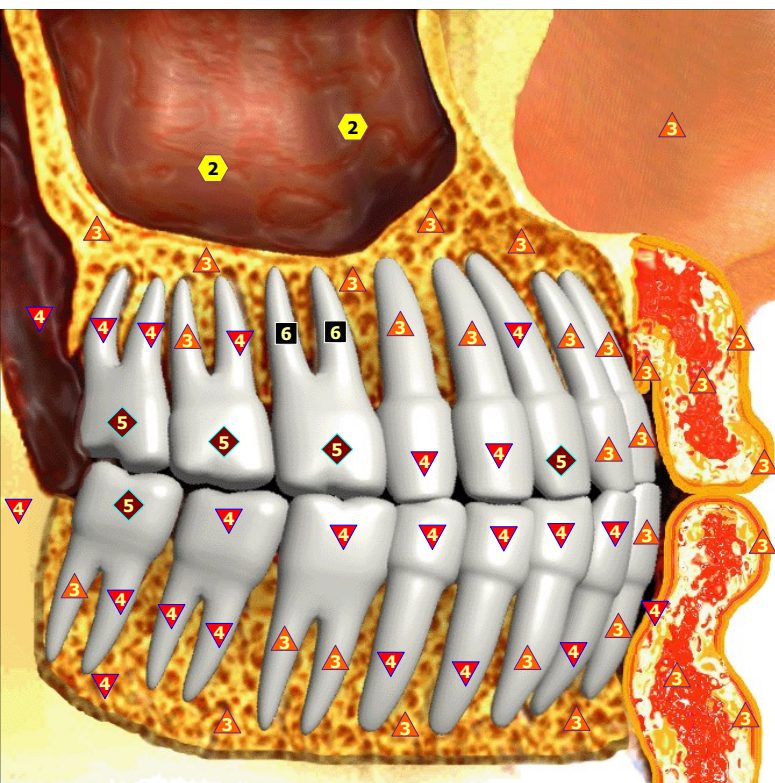
11/09/2024 ORGANS OF MALE SMALL PELVIS; left side



11/09/2024 ORGANS OF RETROPERITONEAL SPACE



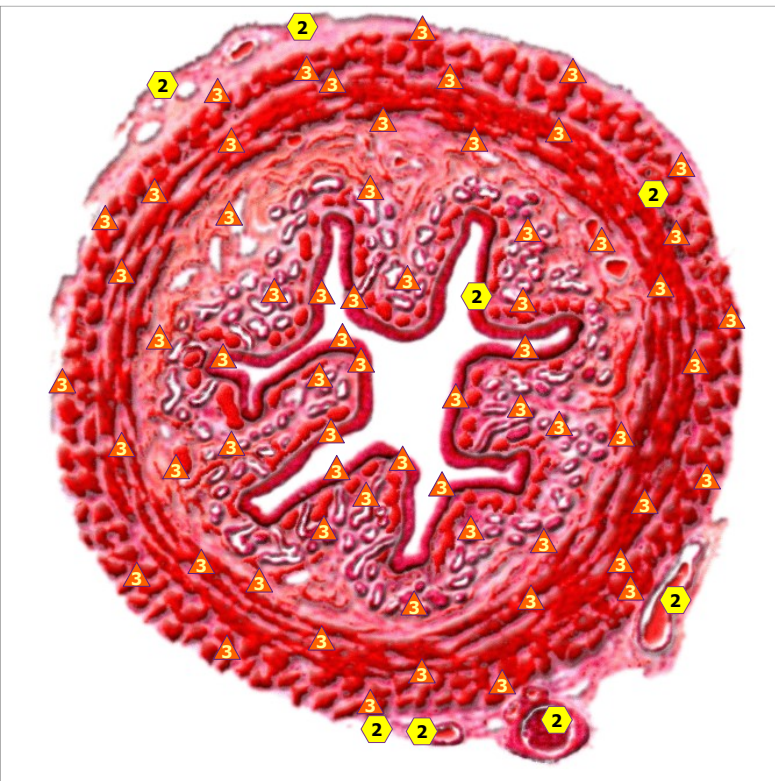
11/09/2024 TEETH; left



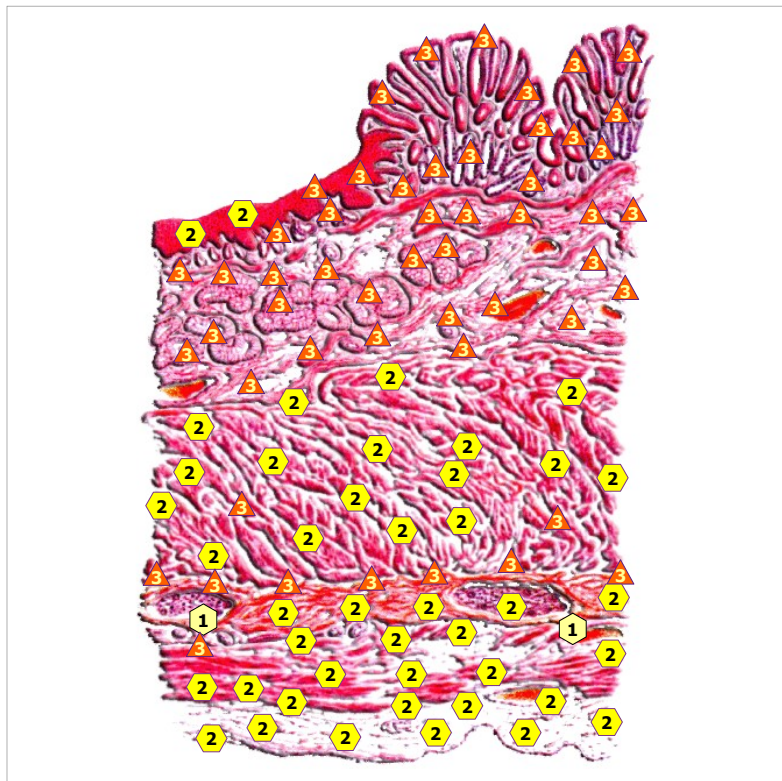
11/09/2024 TEETH; right



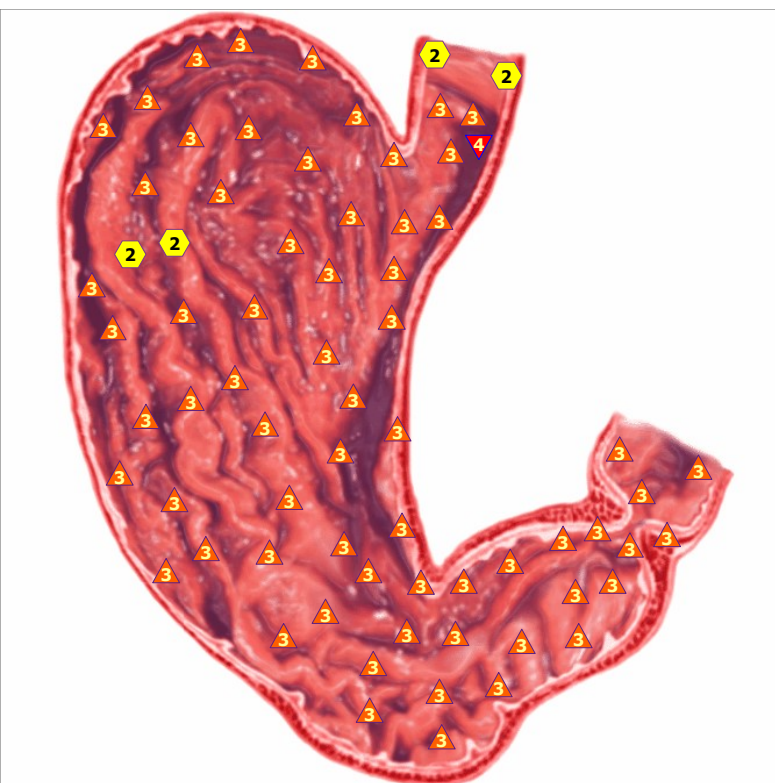
11/09/2024 ESOPHAGUS; front view



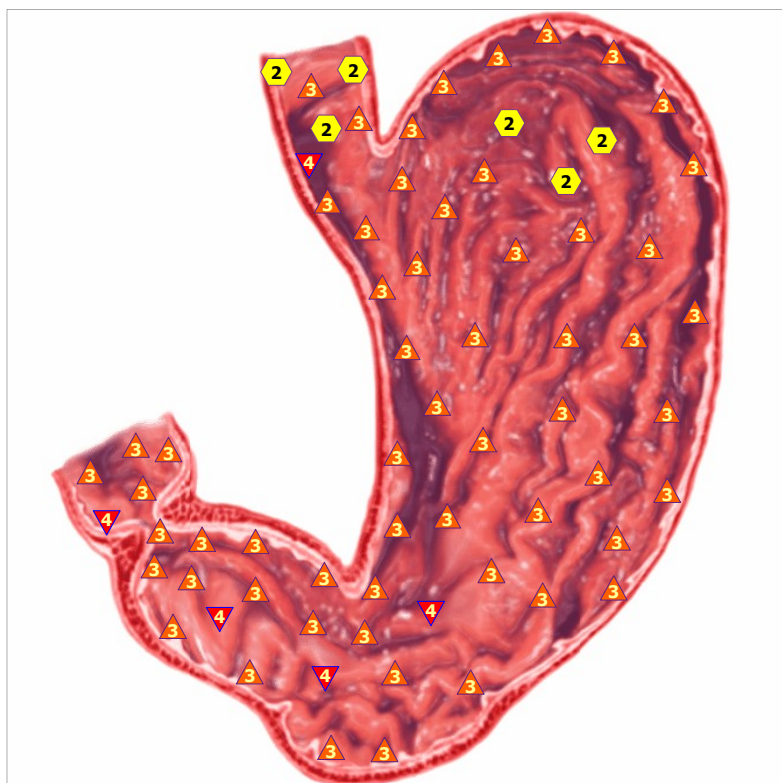
11/09/2024 SECTION OF ESOPHAGUS



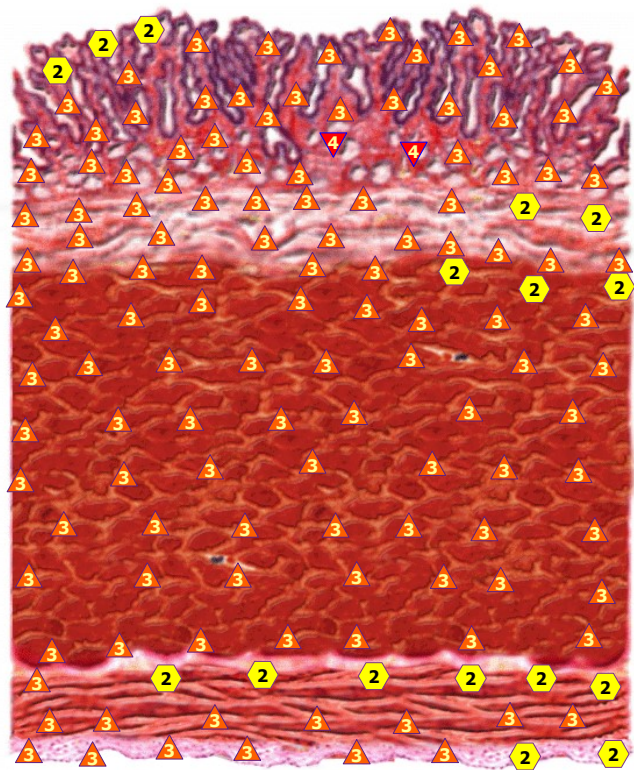
11/09/2024 TRANSITION OF ESOPHAGUS TO STOMACH



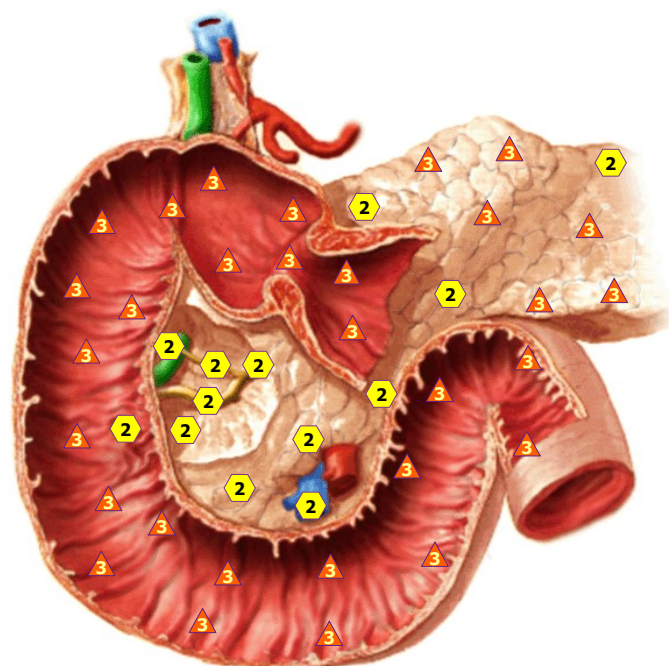
11/09/2024 ANTERIOR WALL OF STOMACH



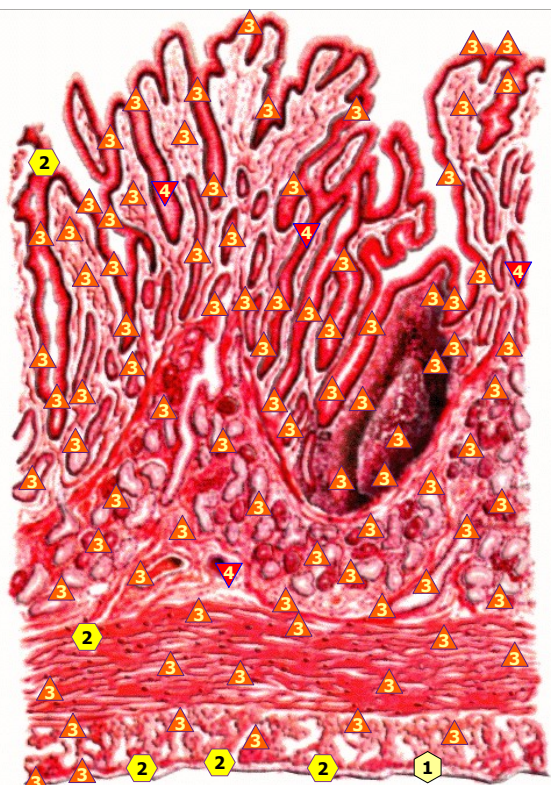
11/09/2024 POSTERIOR WALL OF STOMACH



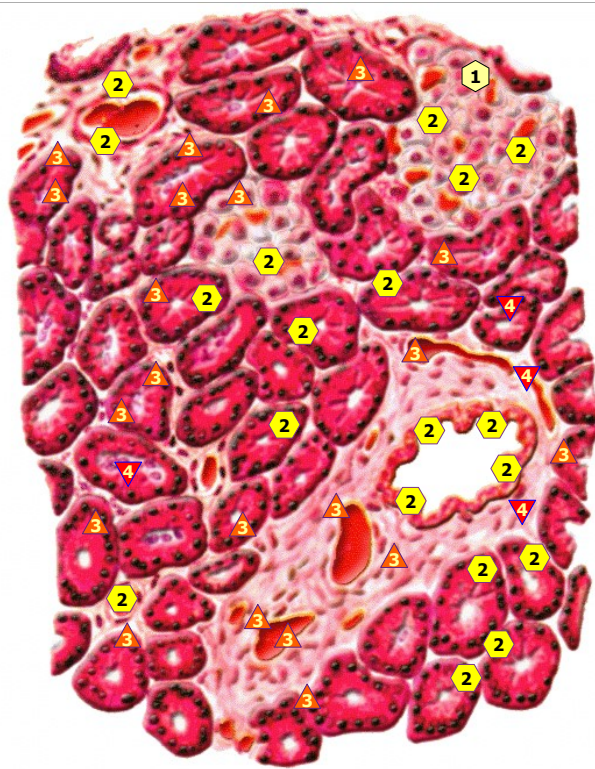
11/09/2024 WALL OF STOMACH



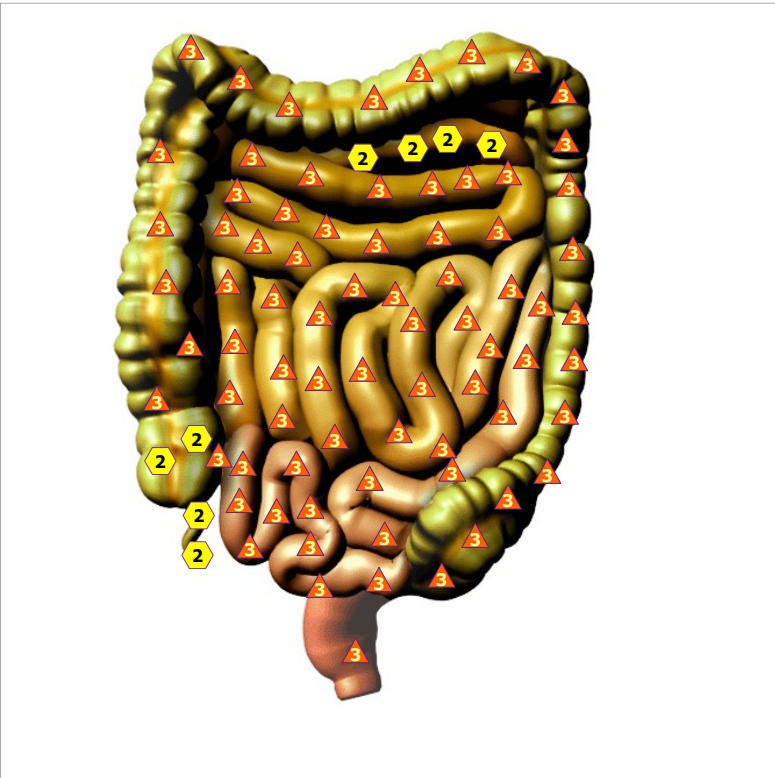11/09/2024 PANCREODUODENAL ZONE; front view



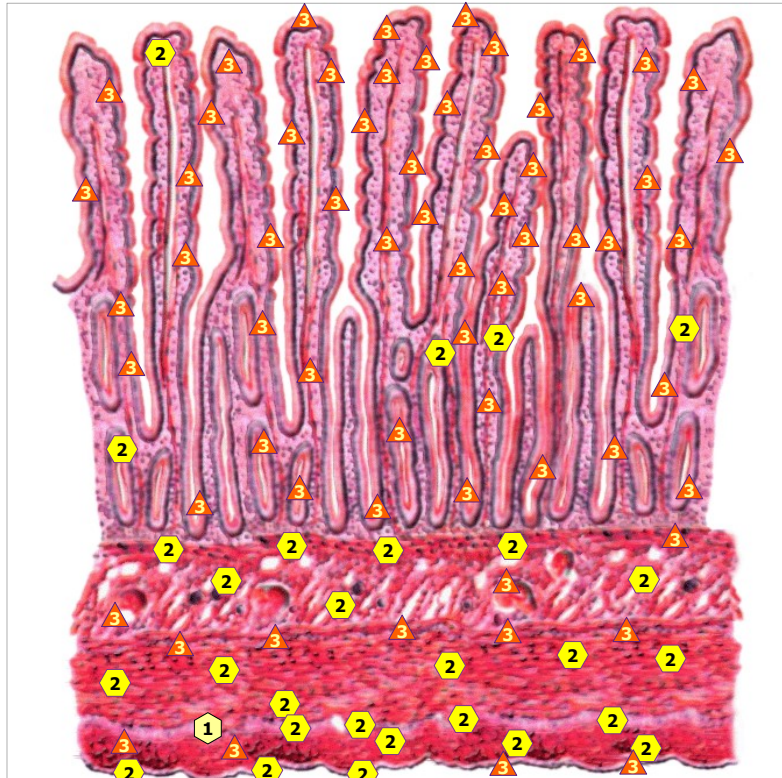
11/09/2024 WALL OF THE DUODENUM



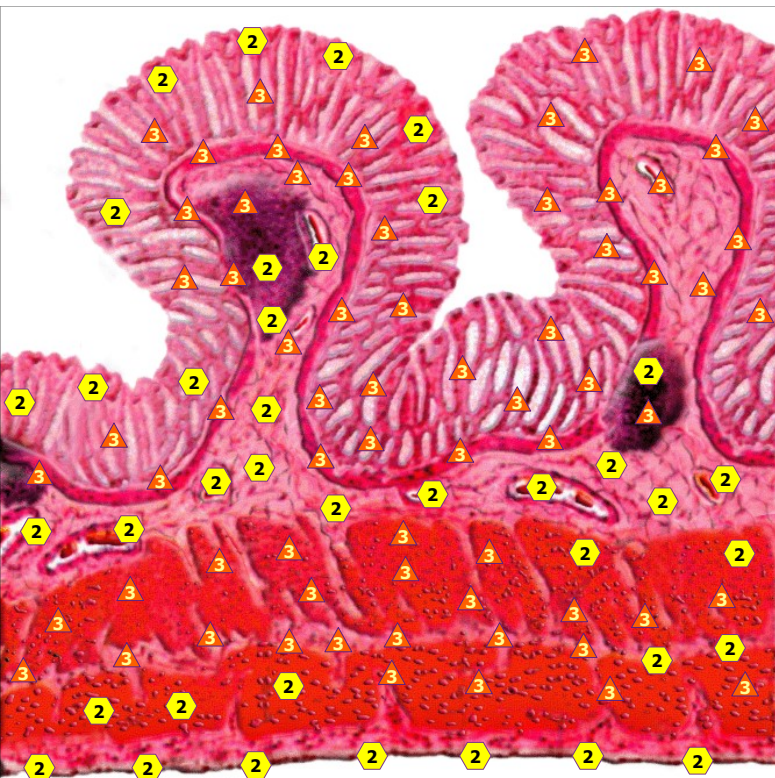
11/09/2024 PANCREAS TISSUE



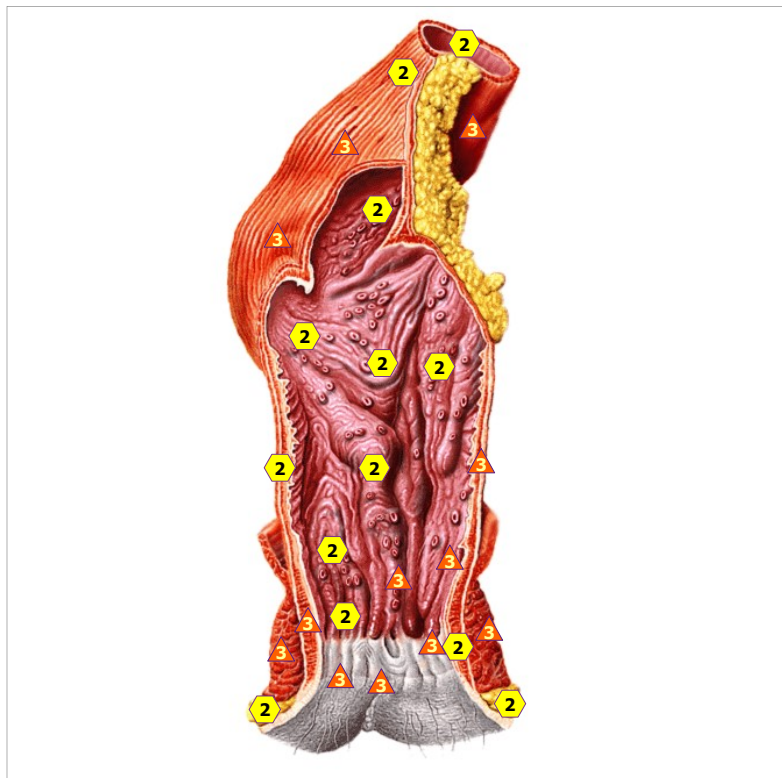
11/09/2024 INTESTINE



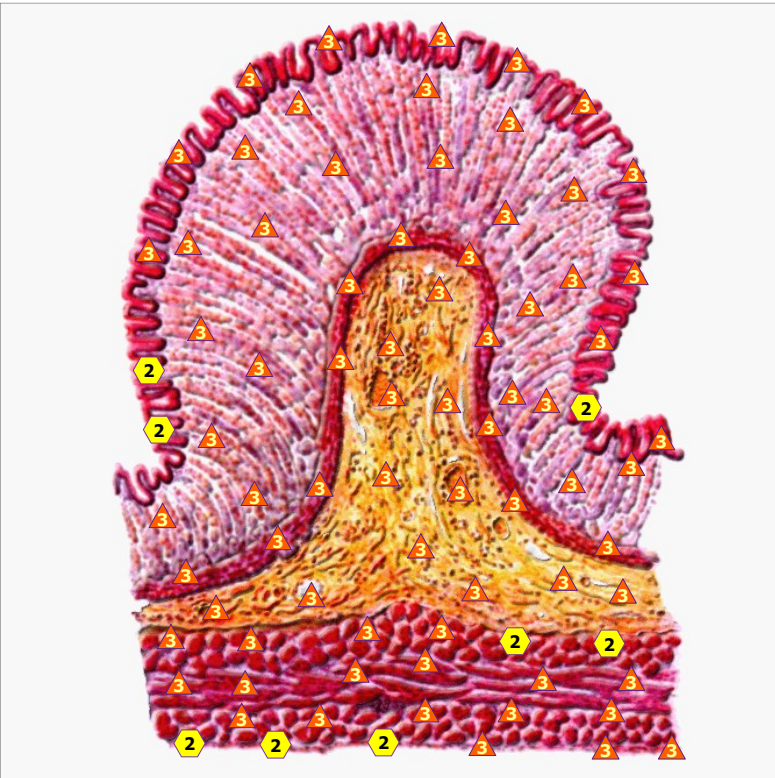
11/09/2024 WALL OF SMALL INTESTINE



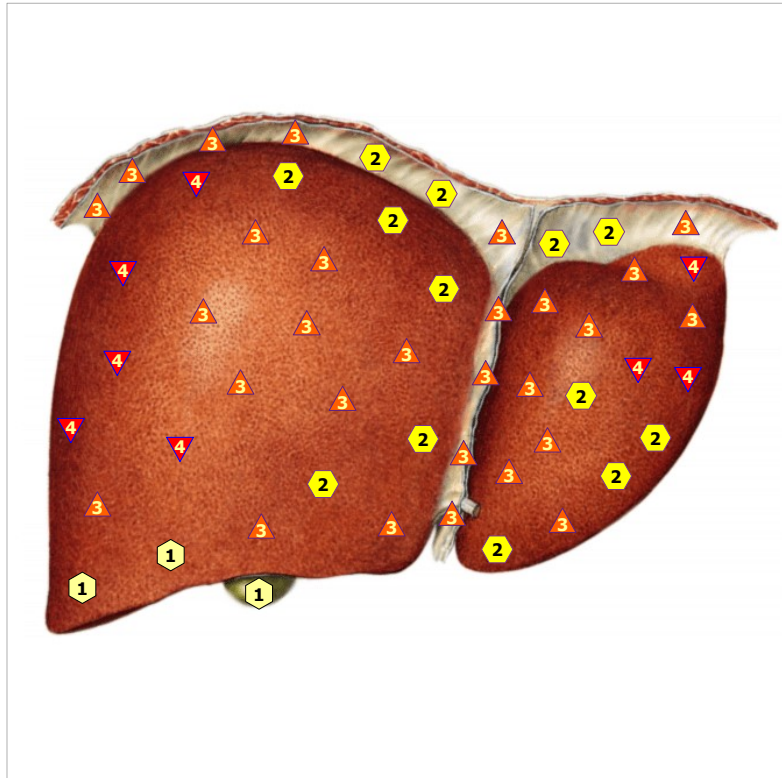
11/09/2024 WALL OF COLON



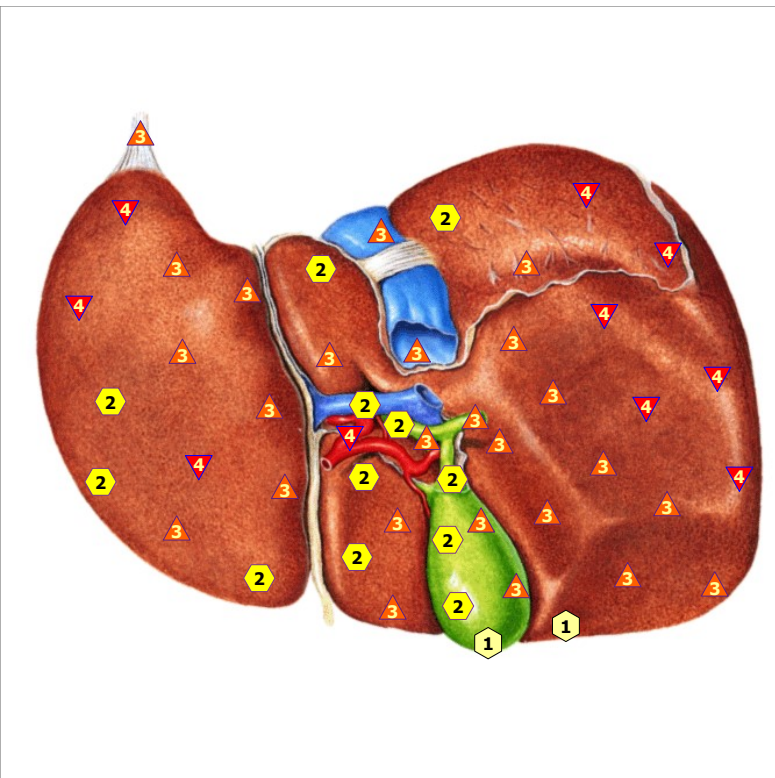
11/09/2024 RECTUM



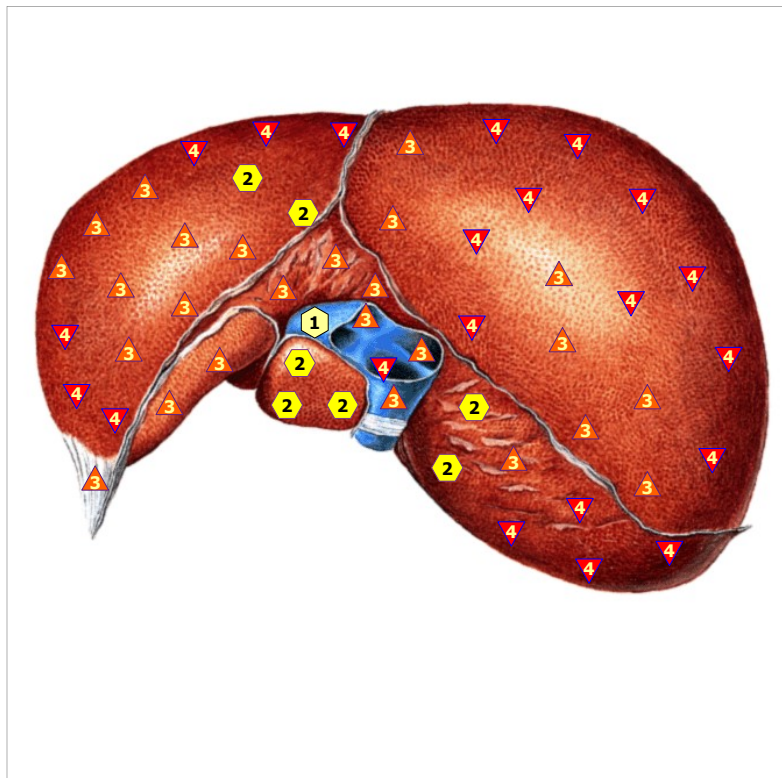
11/09/2024 WALL OF RECTUM



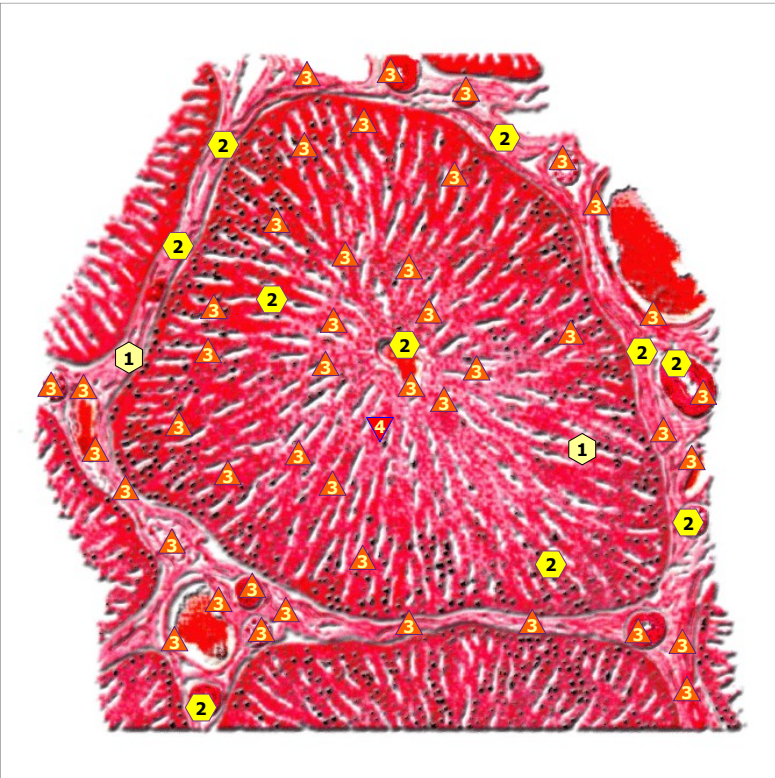
11/09/2024 LIVER; front view



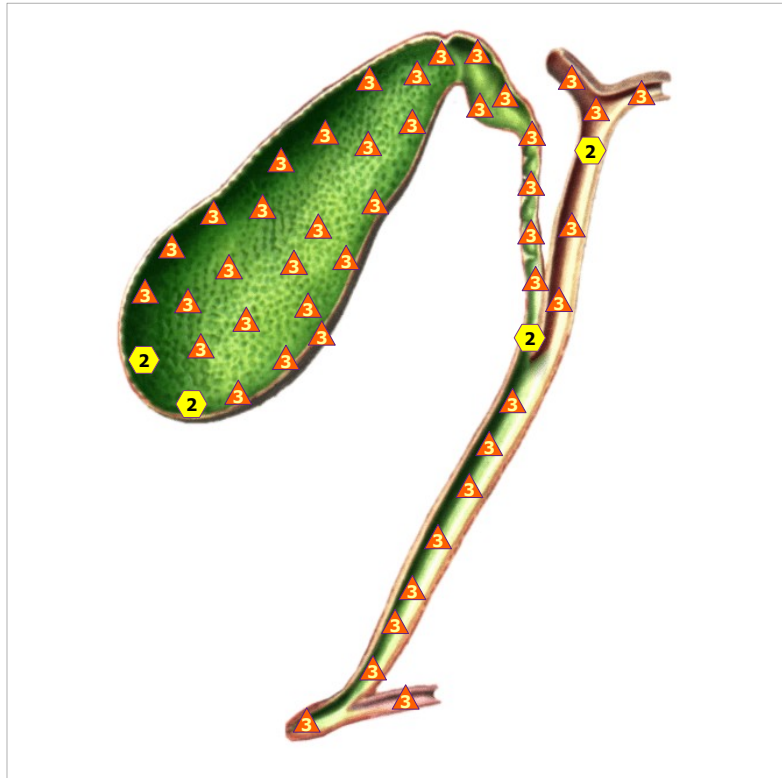
11/09/2024 LIVER; back view



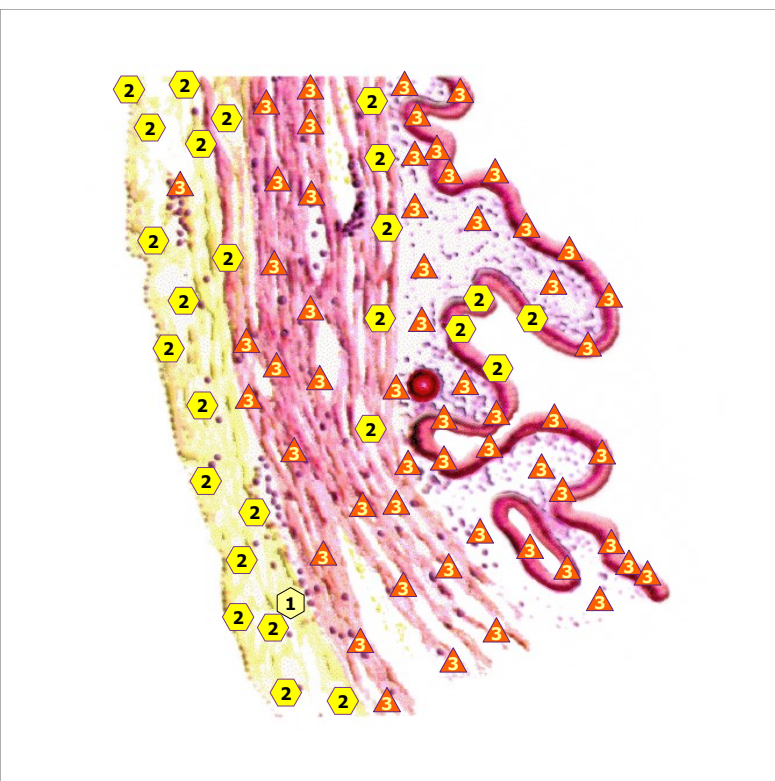
11/09/2024 LIVER; from above



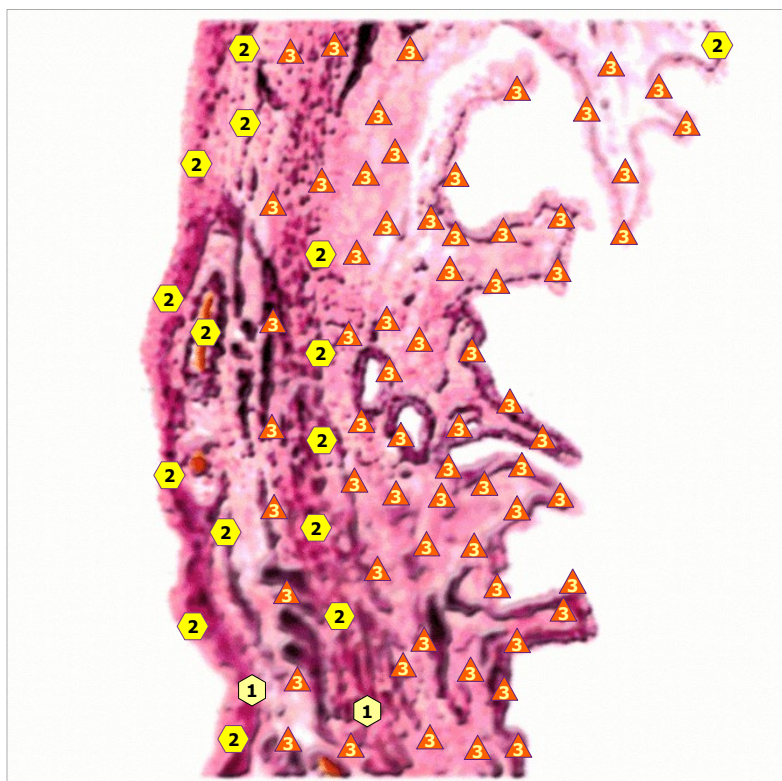
11/09/2024 Hepatic BEAM MC #



11/09/2024 GALL BLADDER

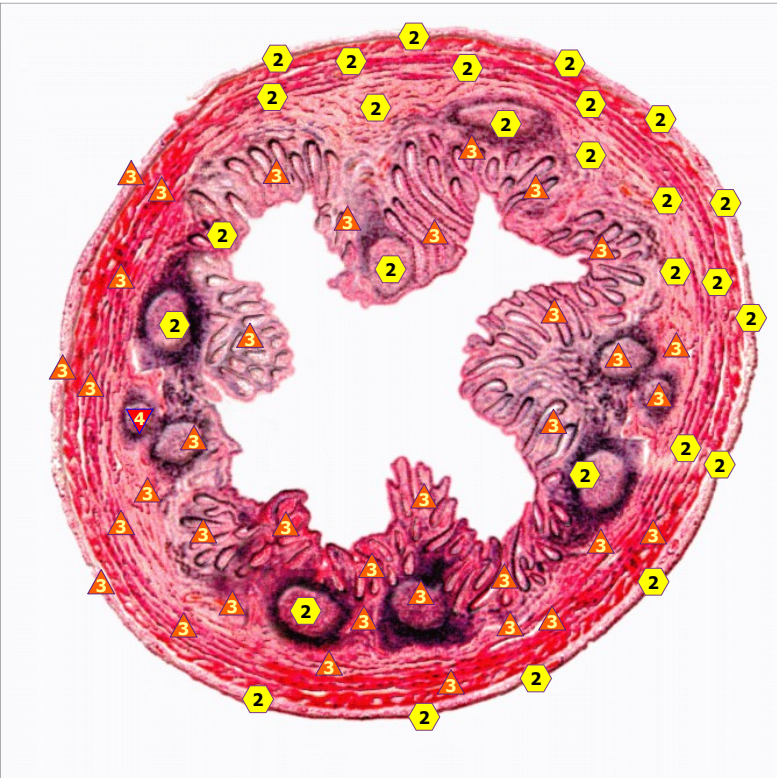


11/09/2024 WALL OF GALL BLADDER

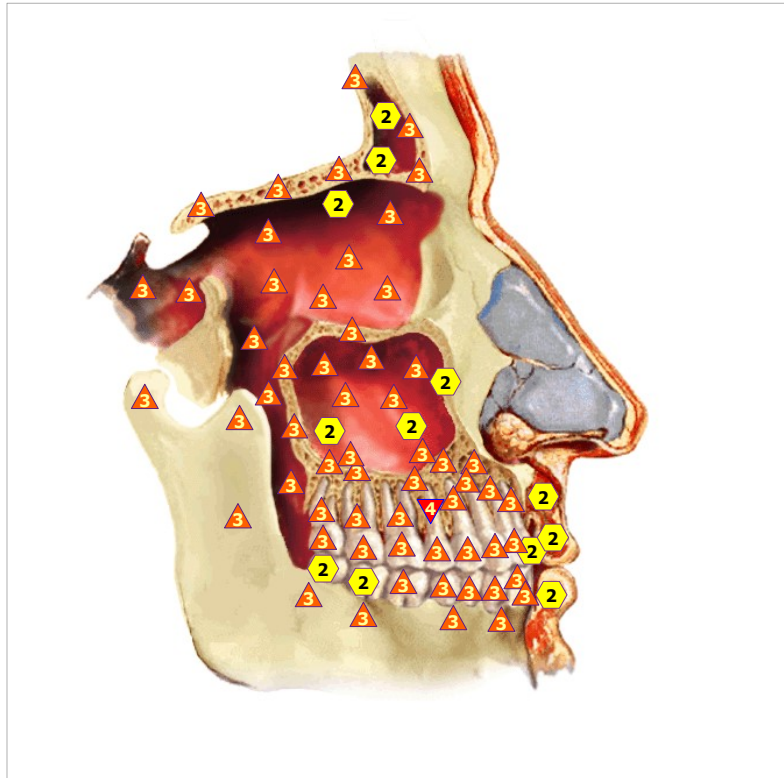


11/09/2024 WALL OF CHOLIC DUCT

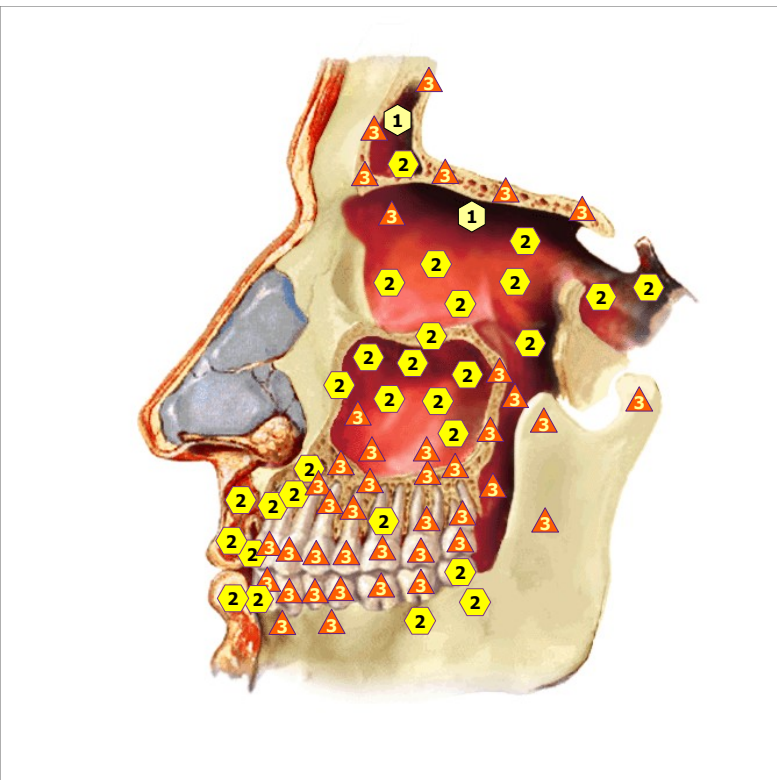




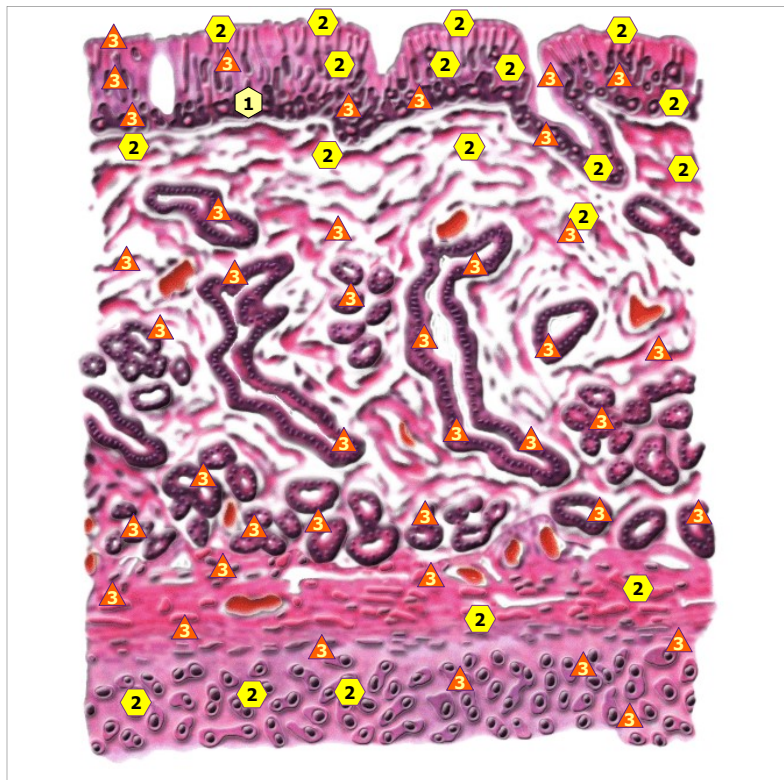
11/09/2024 TRANSVERSAL SECTION OF APPENDIX



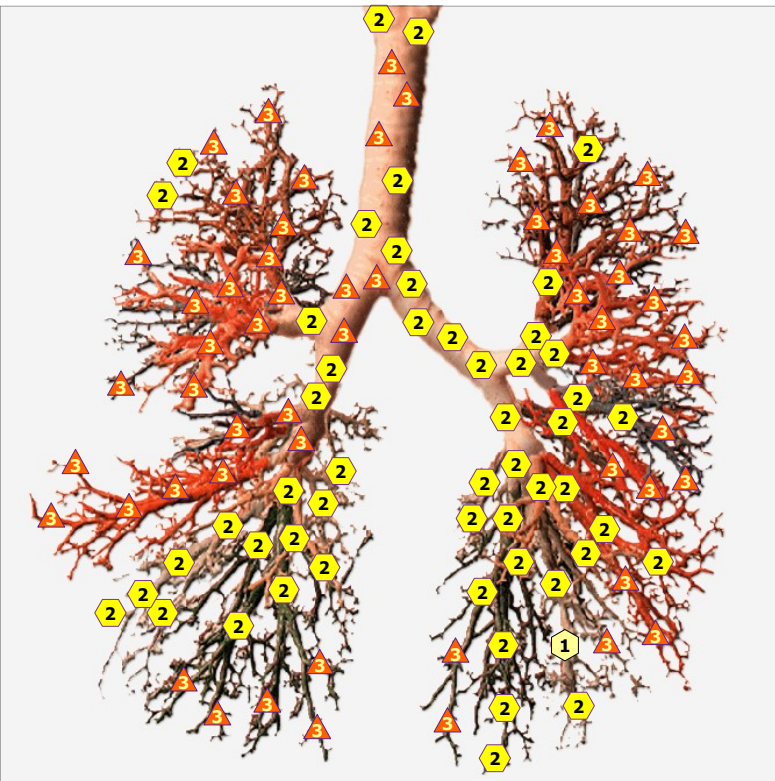
11/09/2024 PARANASAL SINUSES; right view



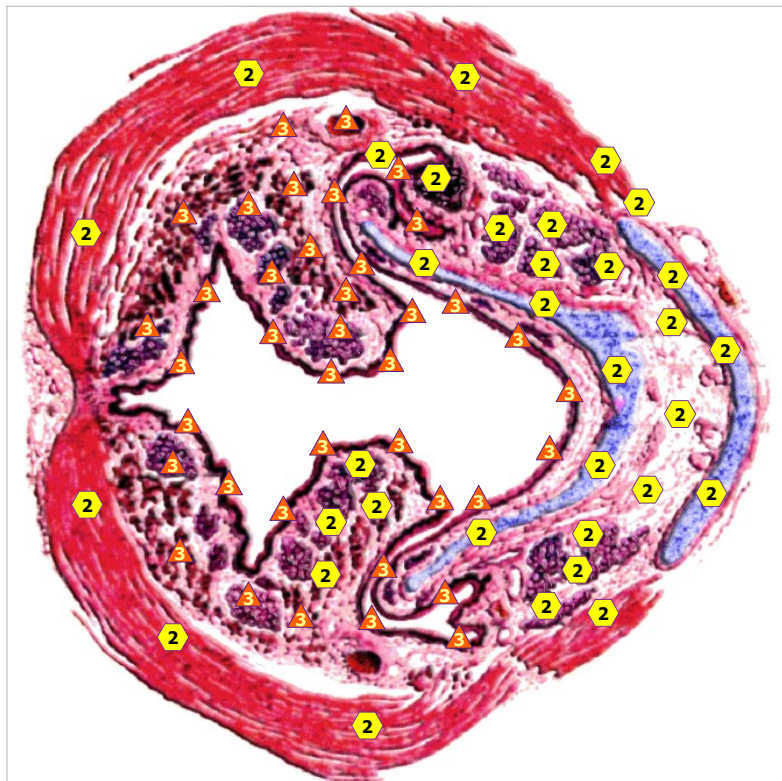
11/09/2024 PARANASAL SINUSES; left view



11/09/2024 MUCOSA OF NASAL CAVITY



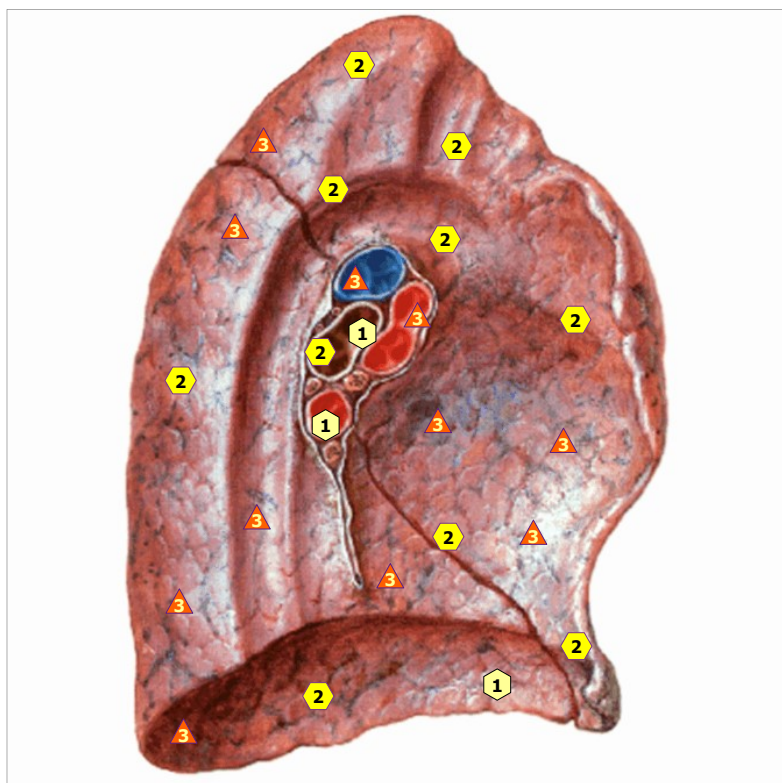
11/09/2024 TRACHEA AND BRONCHI



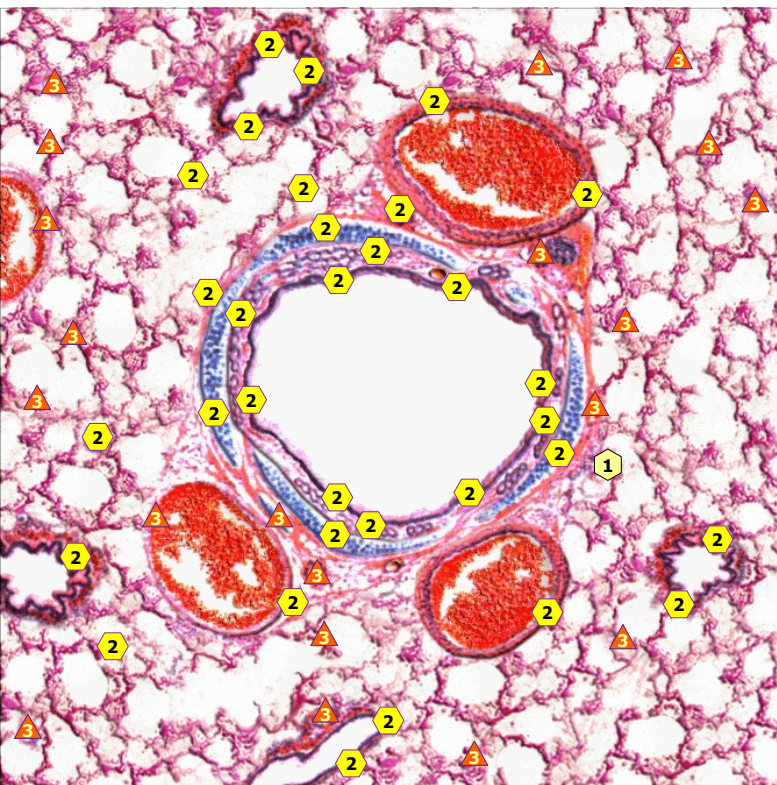
11/09/2024 TRANSVERSAL SECTION OF LARYNX



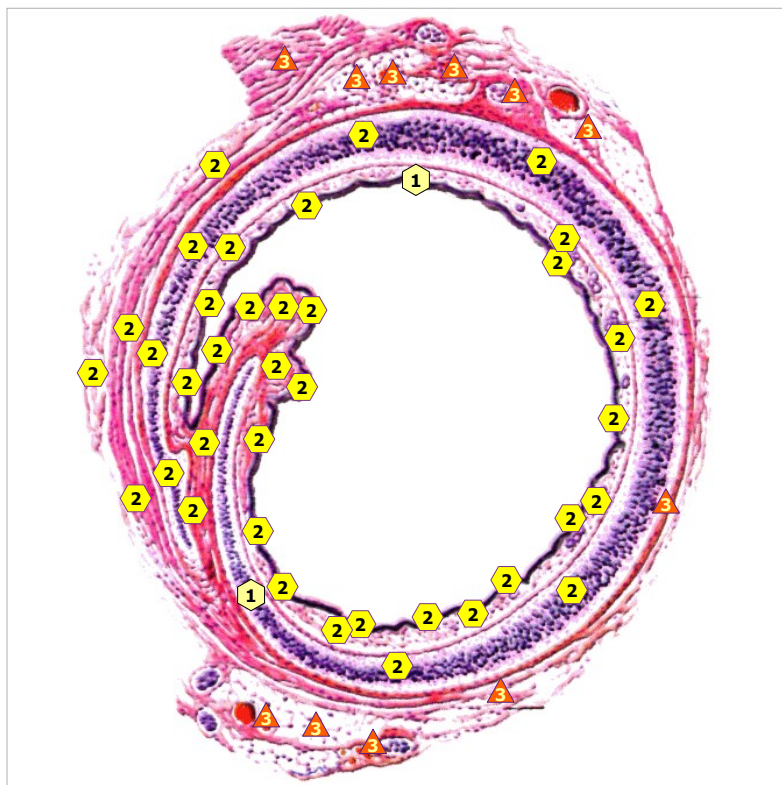
11/09/2024 RIGHT LUNG



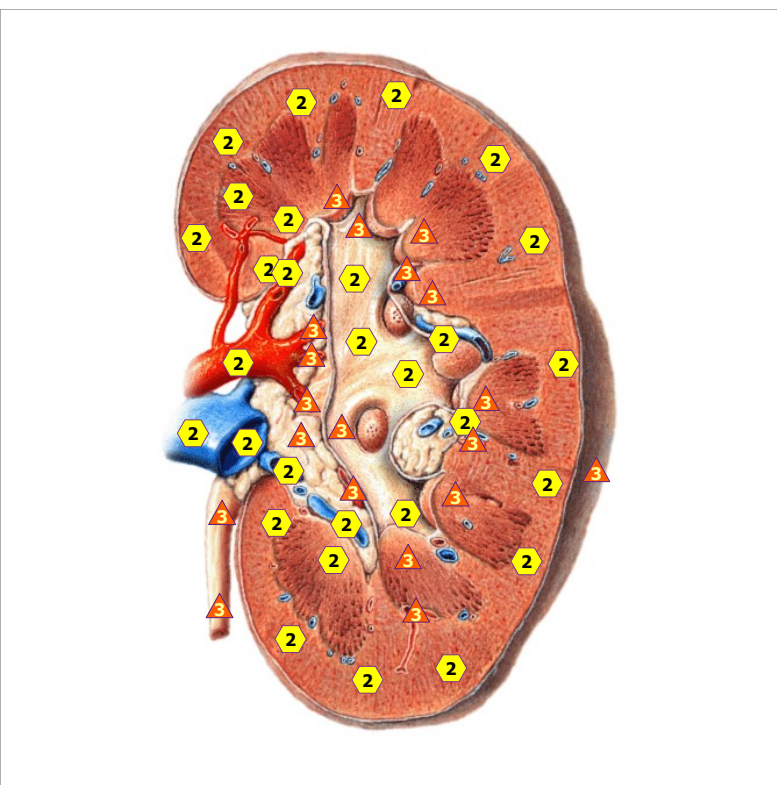
11/09/2024 LEFT LUNG



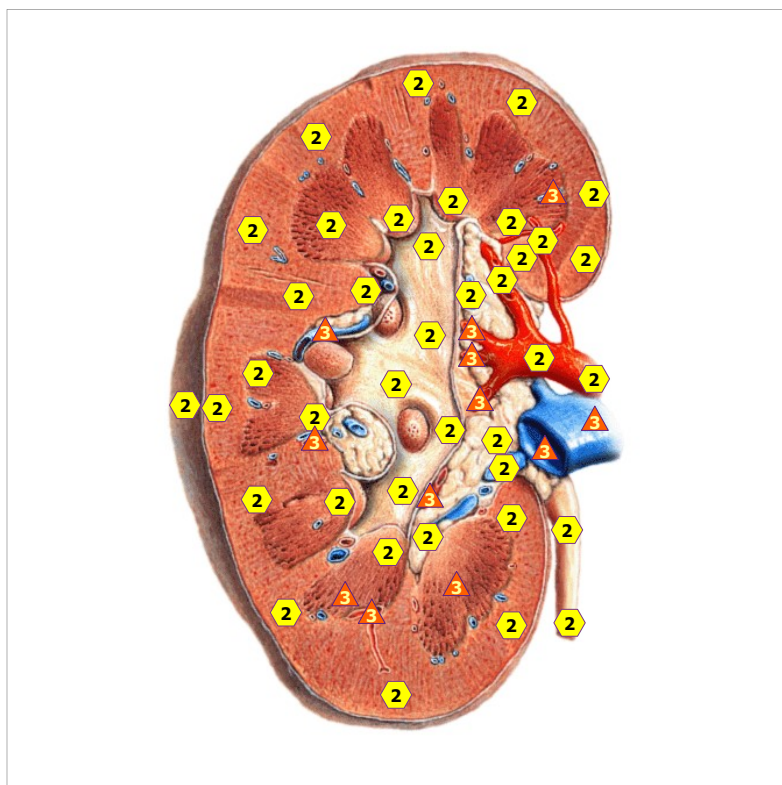
11/09/2024 PULMONARY TISSUE



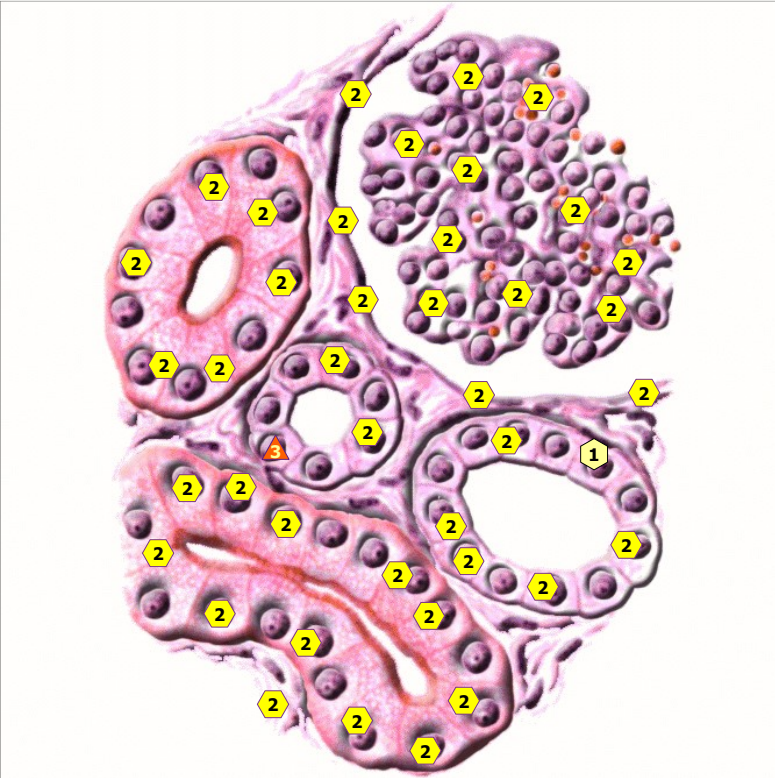
11/09/2024 TRANSVERSAL SECTION OF BRONCHUS



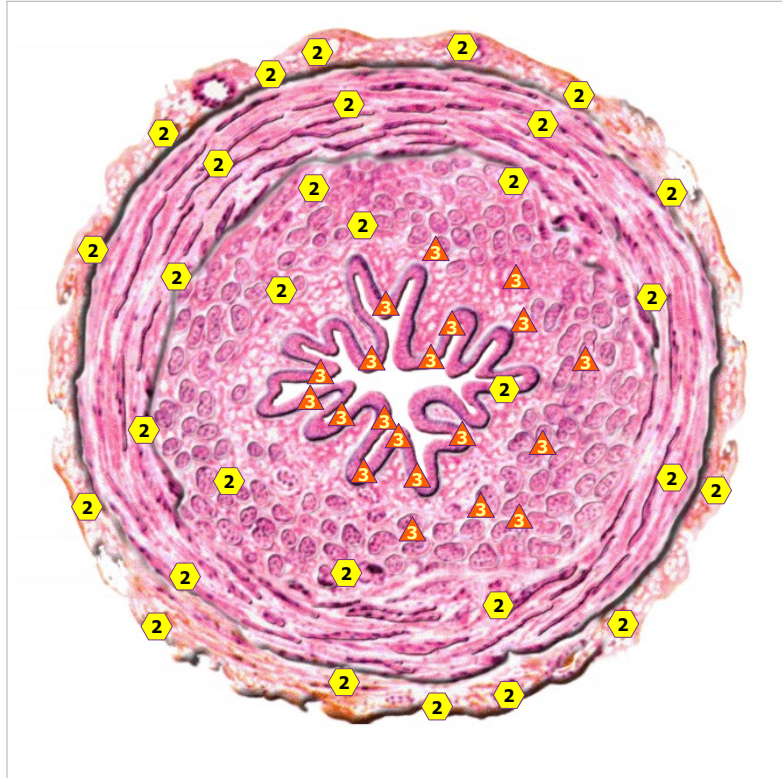
11/09/2024 LONGITUDINAL SECTION OF RIGHT KIDNEY



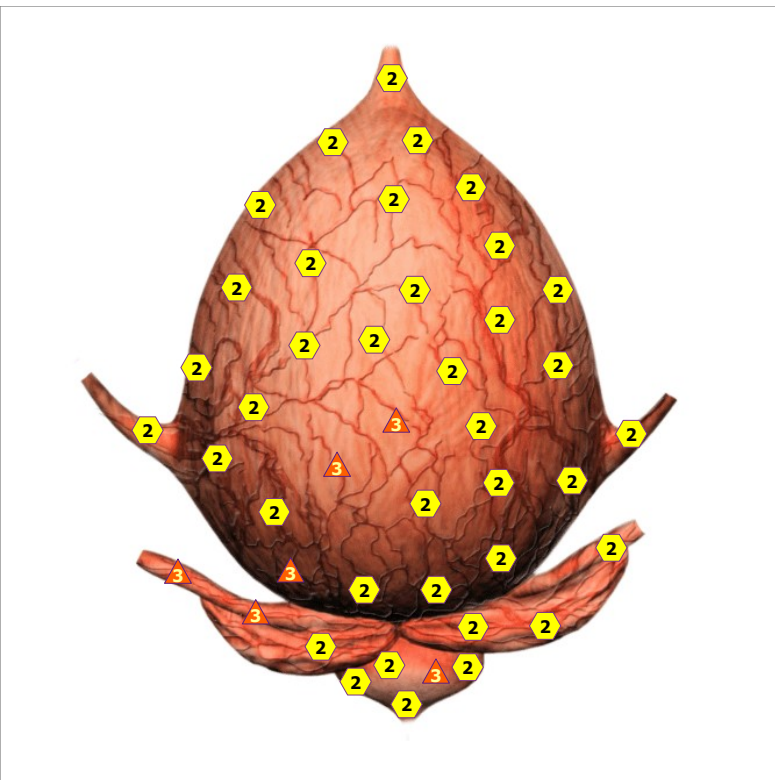
11/09/2024 LONGITUDINAL SECTION OF LEFT KIDNEY



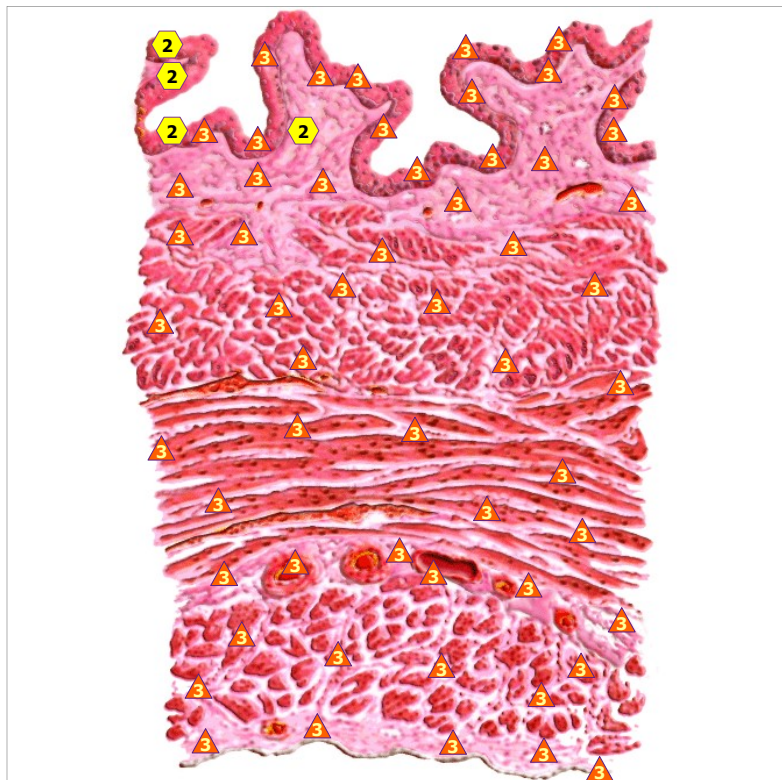
11/09/2024 NEPHRON



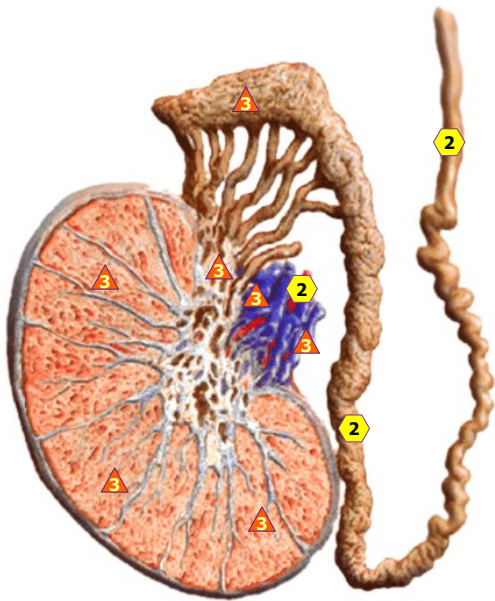
11/09/2024 URETER



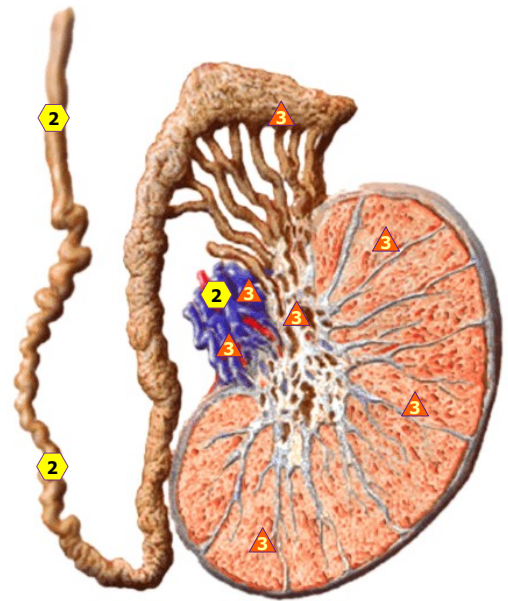
11/09/2024 MALE URINARY BLADDER; rear view



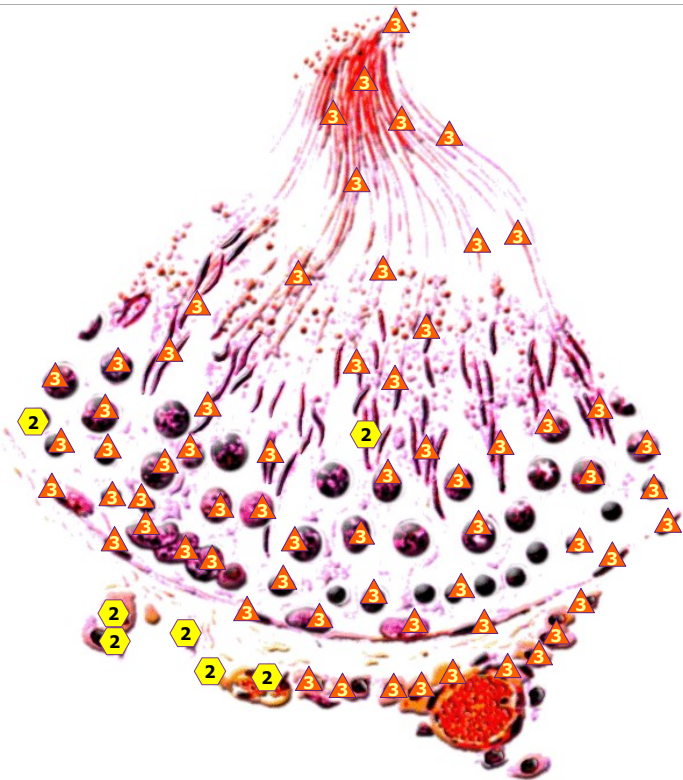
11/09/2024 WALL OF URINARY BLADDER



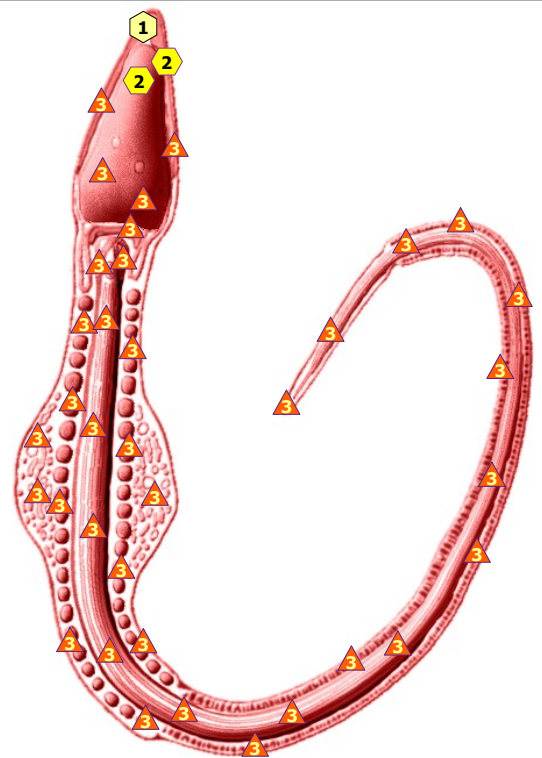
11/09/2024 TESTICLE; right



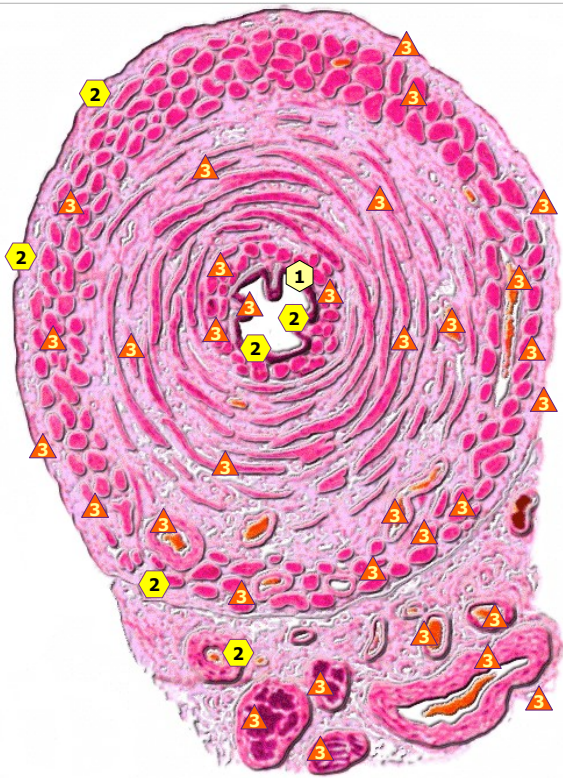
11/09/2024 TESTICLE; left



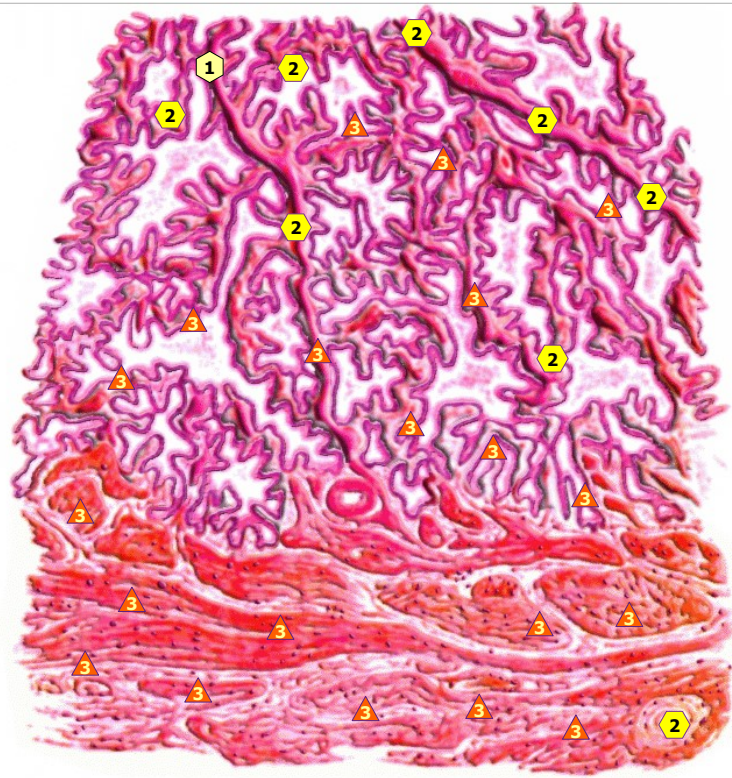
11/09/2024 SECTION OF SEMINAL CANALICULUS



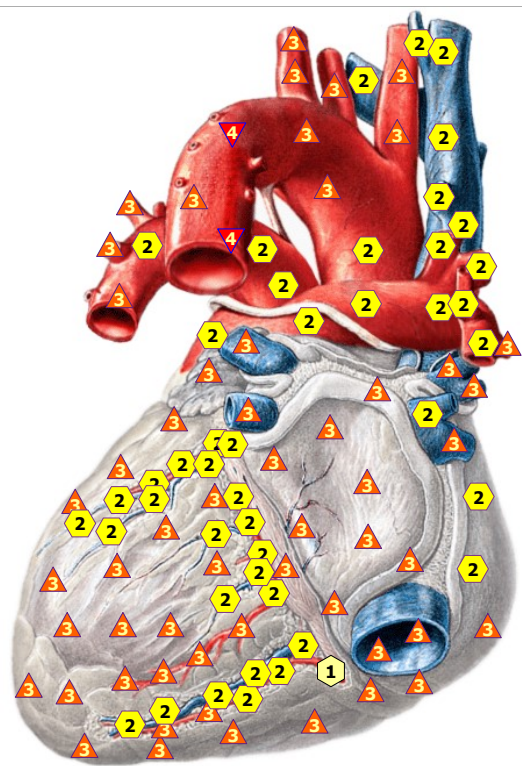
11/09/2024 SPERMATOZOON



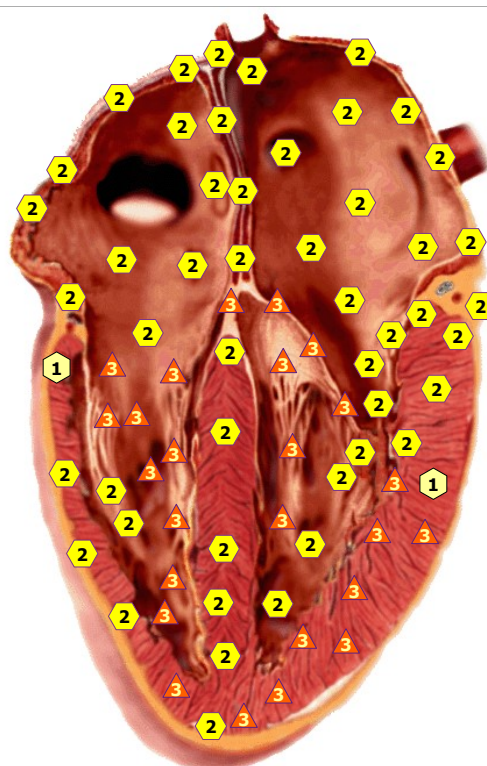
11/09/2024 URETHRA



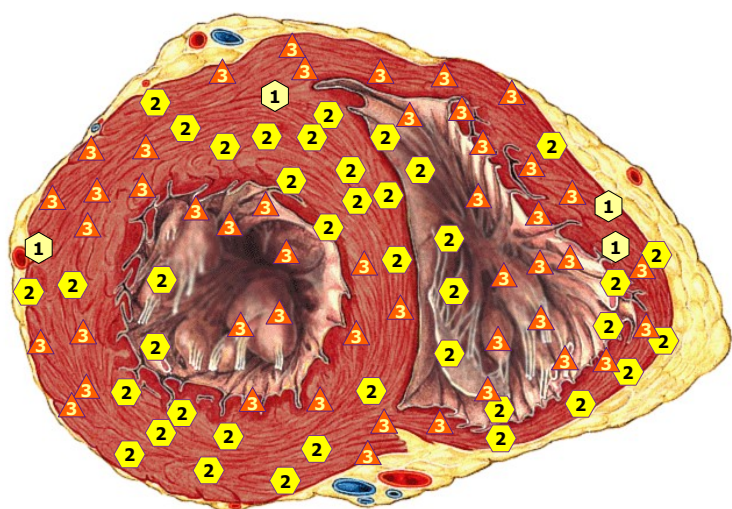
11/09/2024 PROSTATE



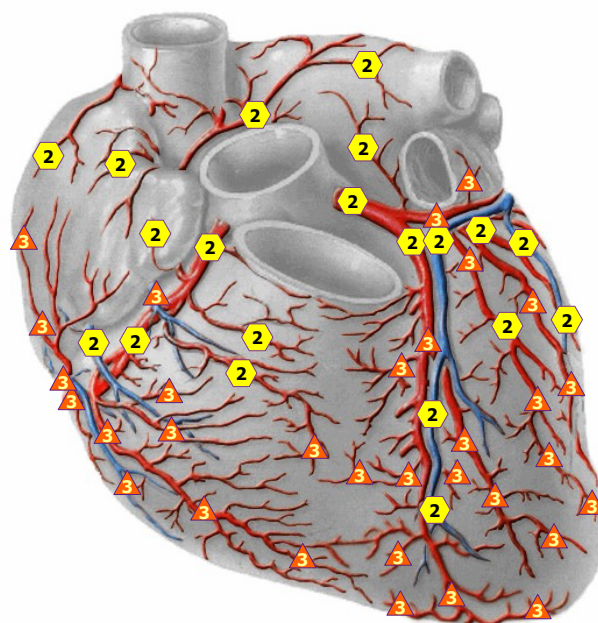
11/09/2024 HEART; from the behind



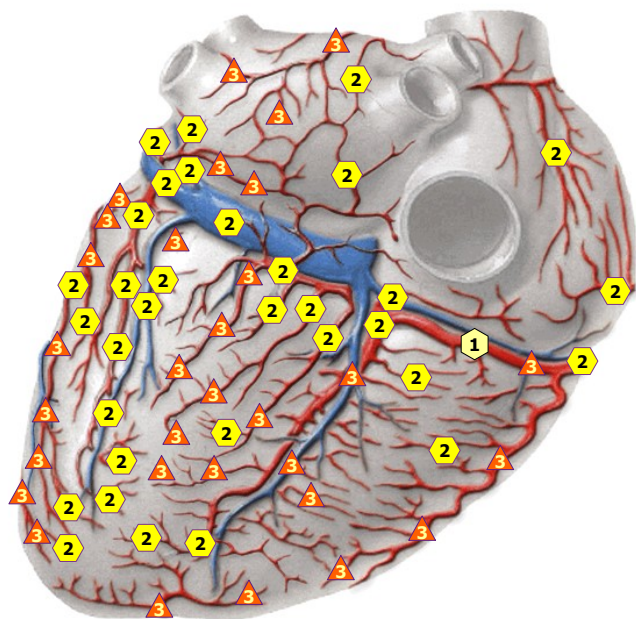
11/09/2024 LONGITUDINAL CROSS-SECTION OF HEART



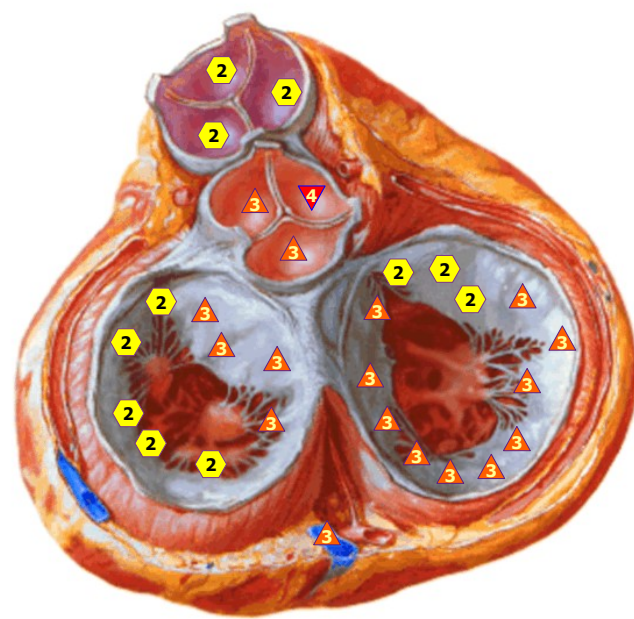
11/09/2024 TRANSVERSAL SECTION OF HEART



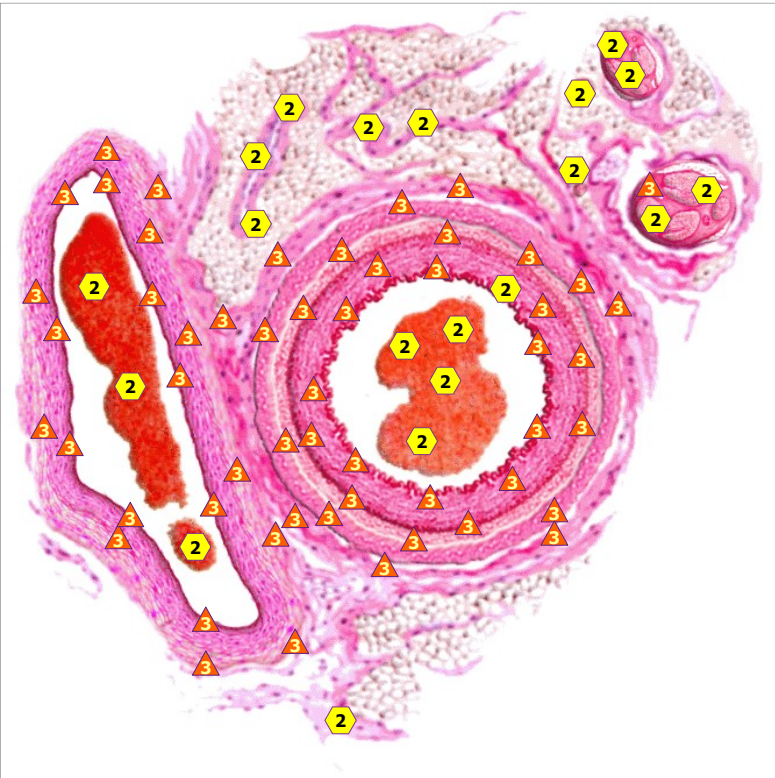
11/09/2024 VESSELS OF FRONTAL WALL OF HEART



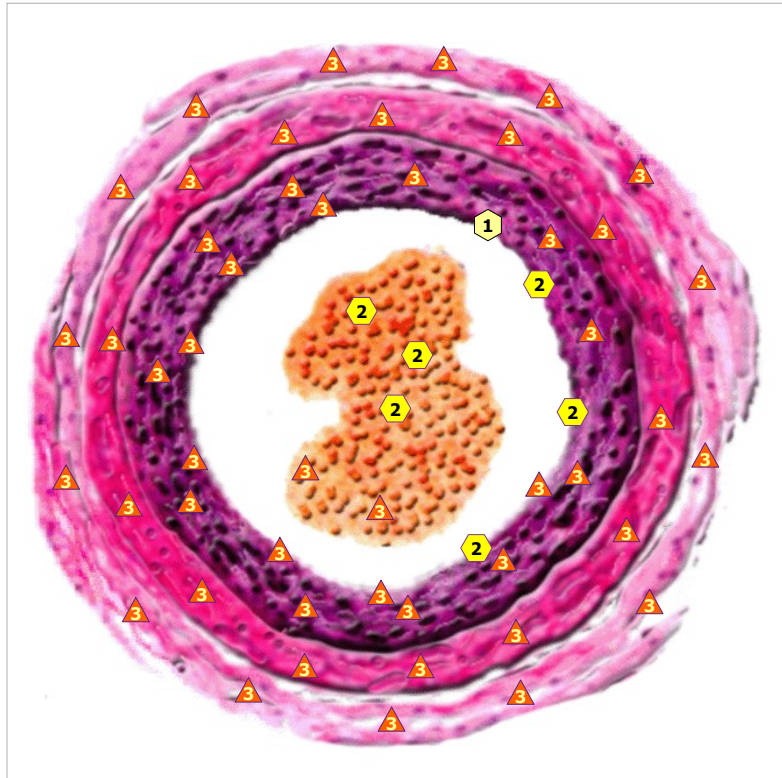
11/09/2024 VESSELS OF POSTERIOR HEART WALL



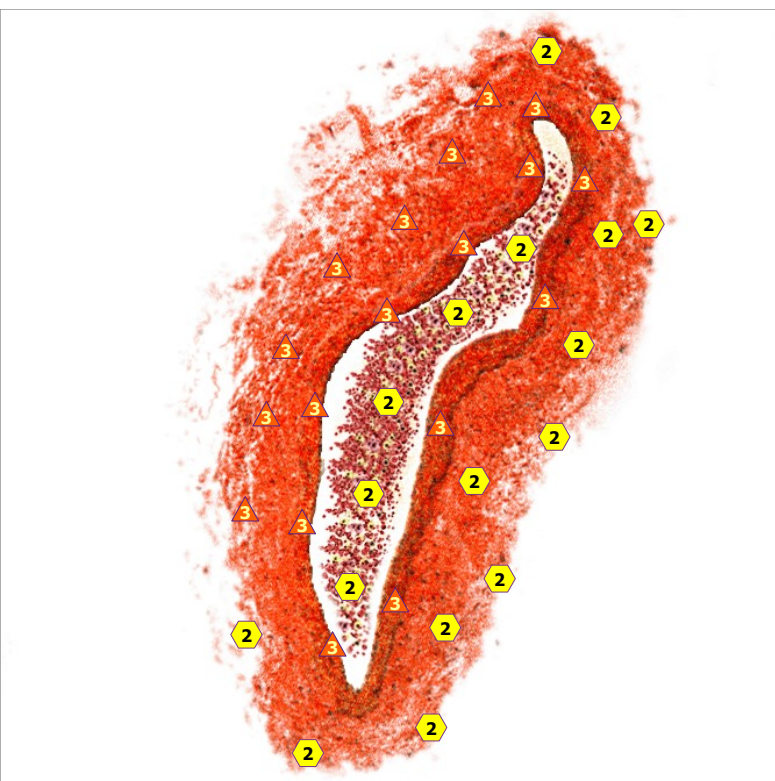
11/09/2024 VALVES OF HEART



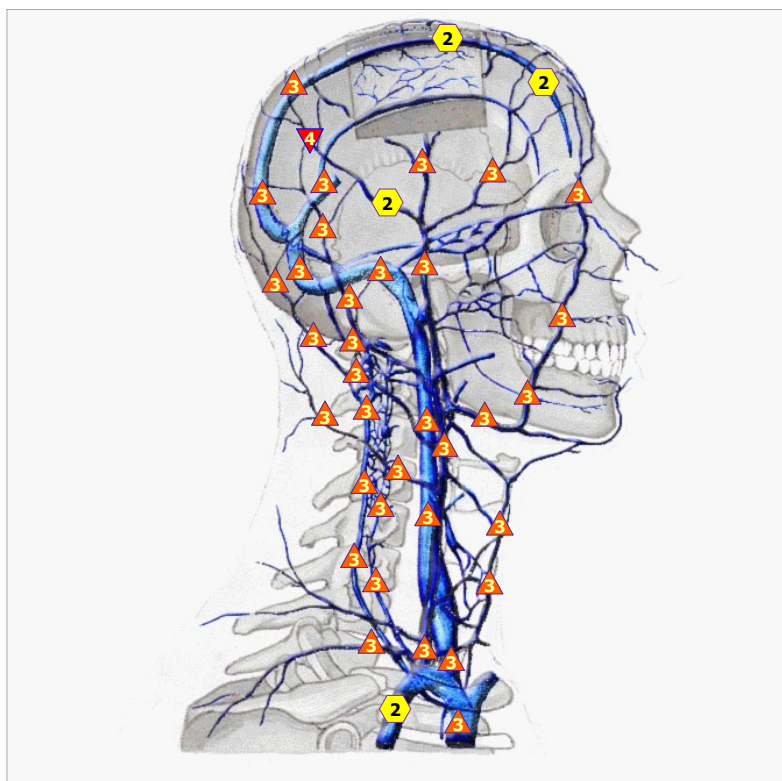
11/09/2024 NEURO - VESSEL FASCICLE



11/09/2024 WALL OF ARTERIAL VESSEL

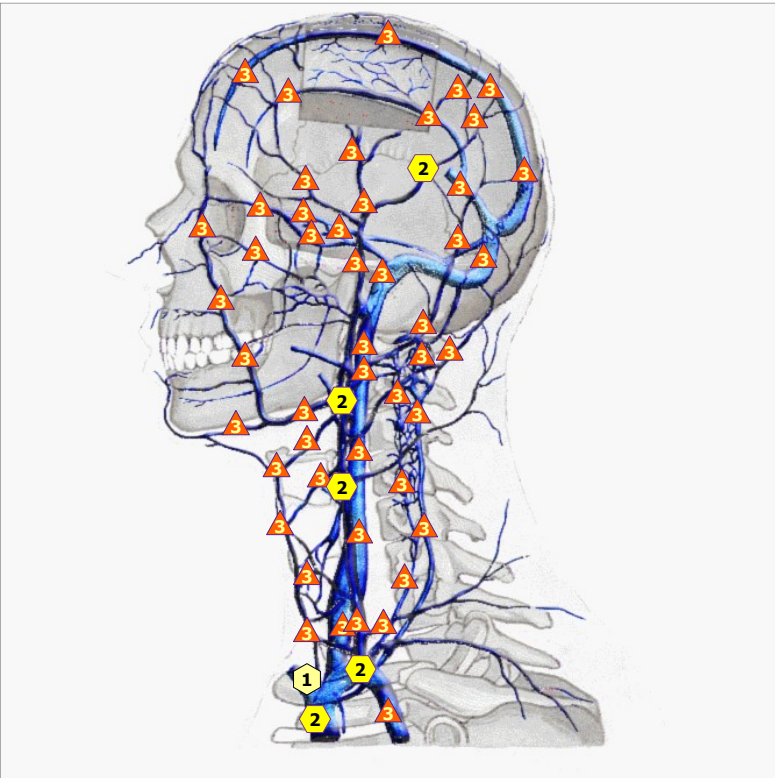


11/09/2024 TRANSVERSAL SECTION OF VEIN VESSEL

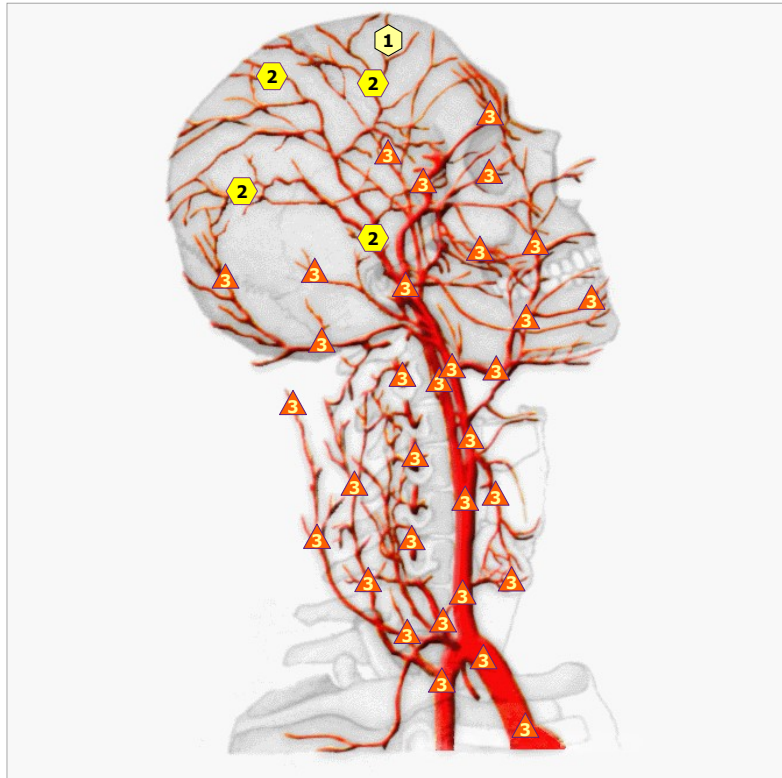


11/09/2024 VEINS IN THE HEAD AND NECK AREAS,RIGHT SIDE

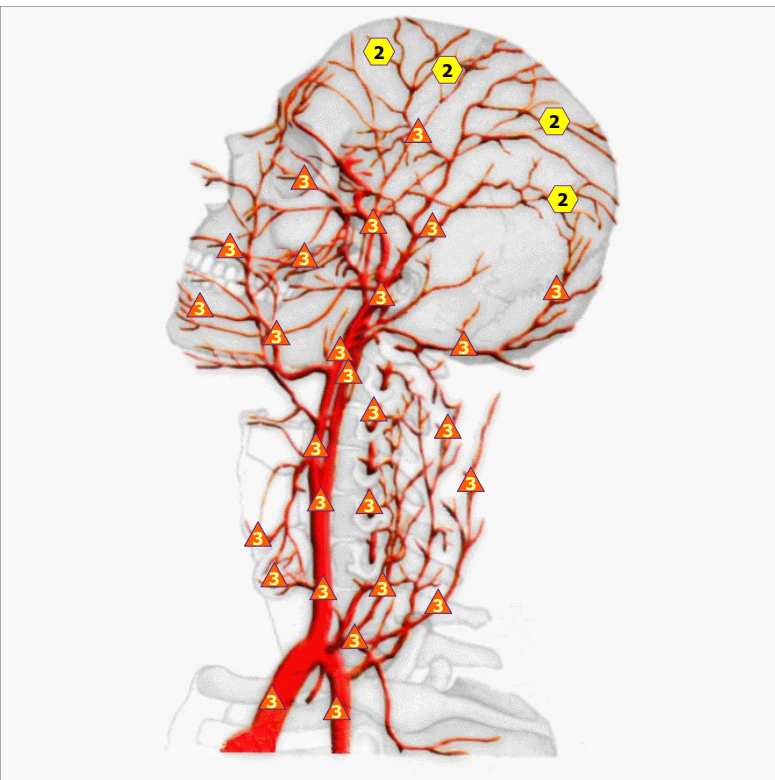




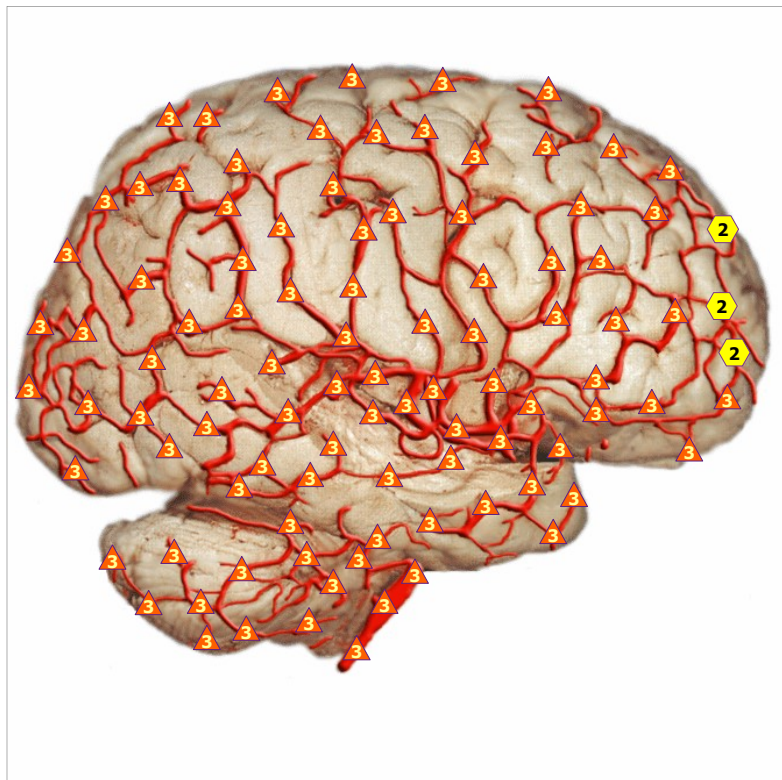
11/09/2024 VEINS IN THE HEAD AND NECK AREAS, LEFT SIDE



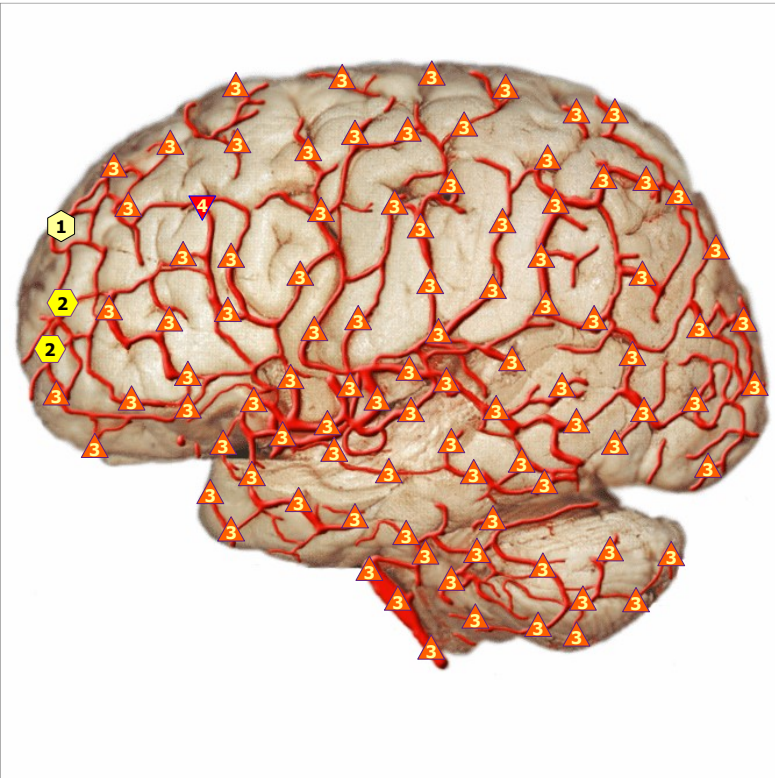
11/09/2024 ARTERIES OF HEAD AND NECK; RIGHT SIDE



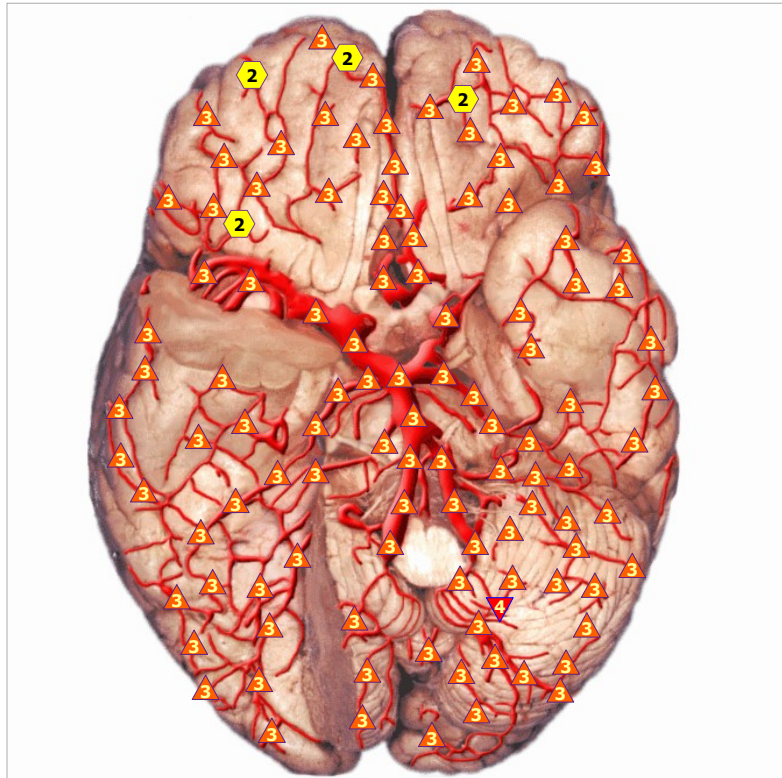
11/09/2024 ARTERIES OF HEAD AND NECK; LEFT SIDE



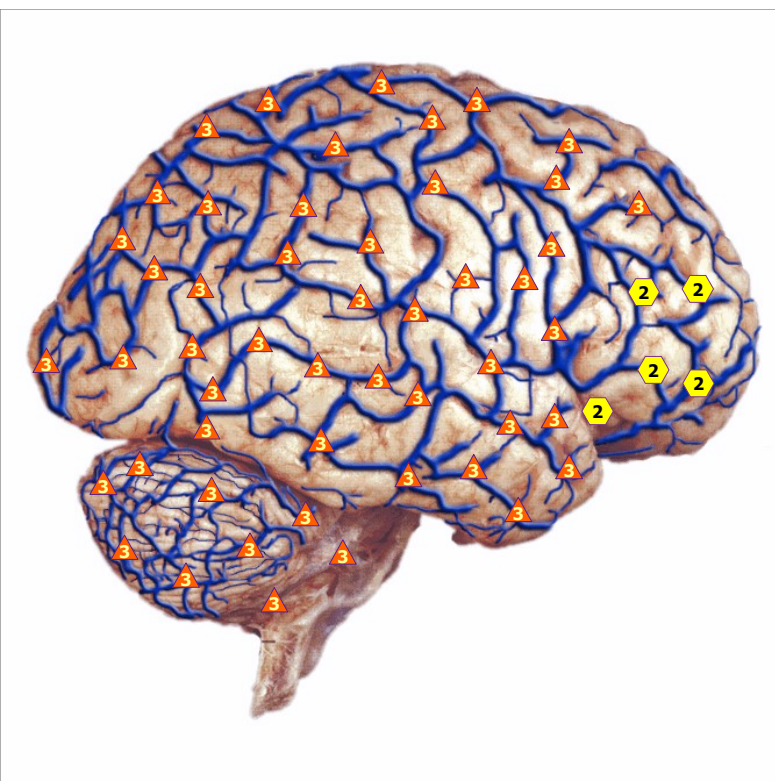11/09/2024 CEREBRAL ARTERIES, lateral view of right hemisphere



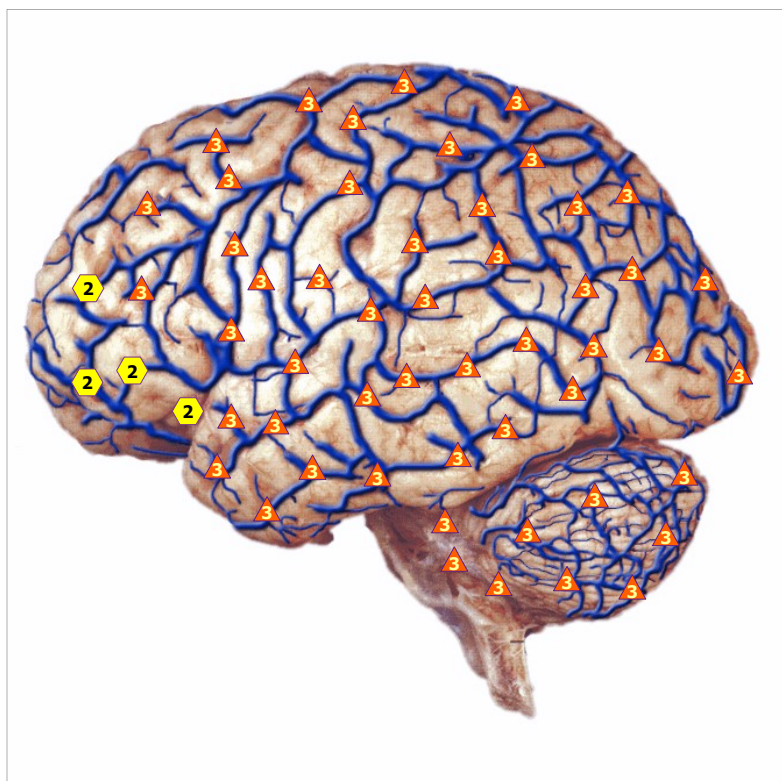
11/09/2024 CEREBRAL ARTERIES, lateral view of left hemisphere



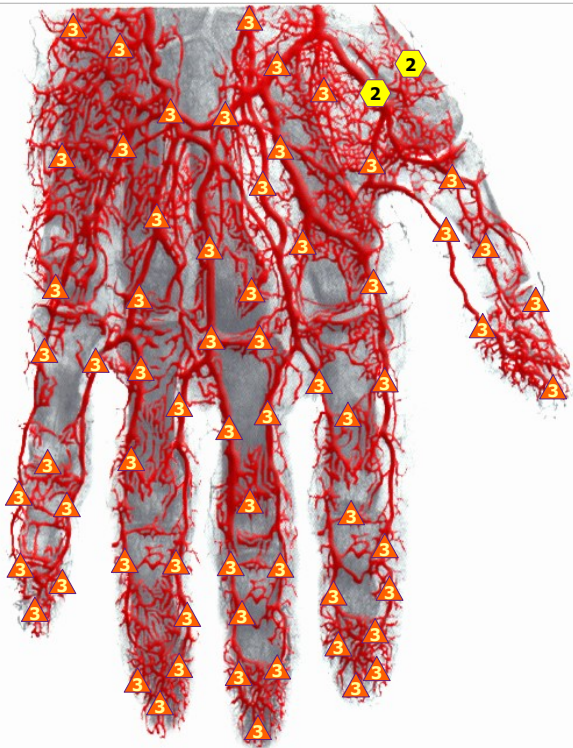
11/09/2024 ARTERIES OF BRAIN, VIEW FROM BELOW



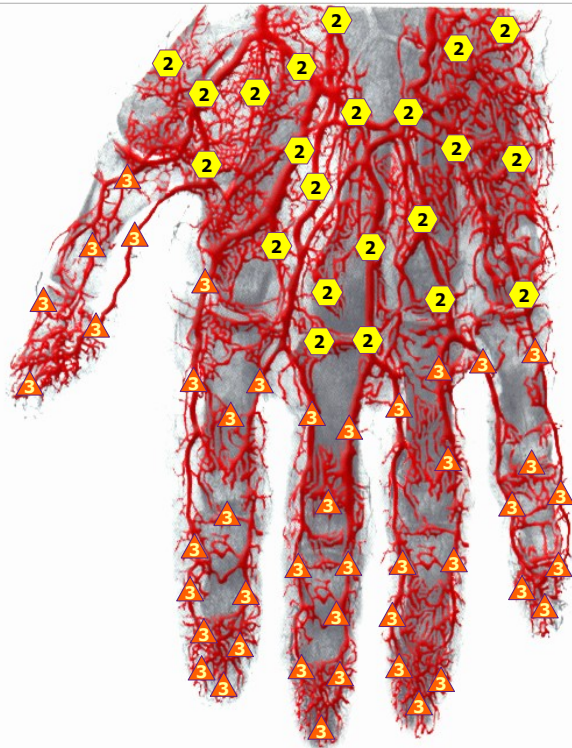
11/09/2024 CEREBRAL VEINS of right hemisphere



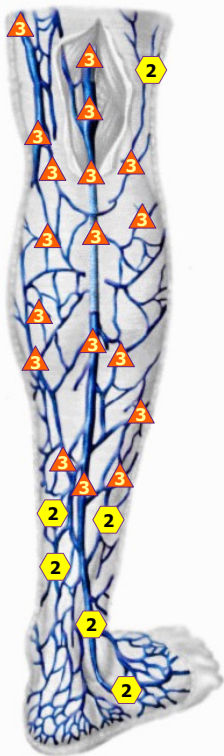
11/09/2024 CEREBRAL VEINS of left hemisphere



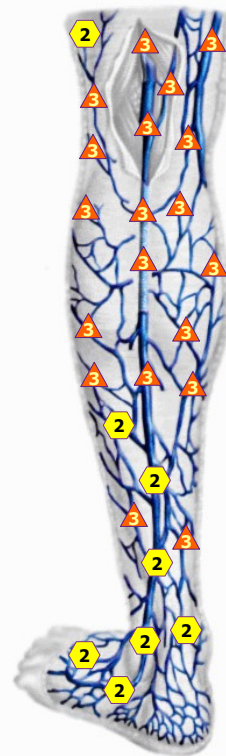11/09/2024 ARTERY RIGHT HAND



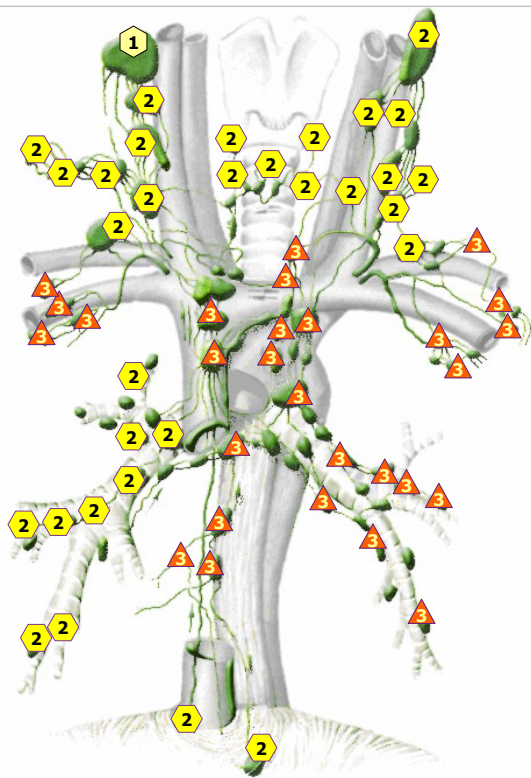
11/09/2024 ARTERY LEFT HAND



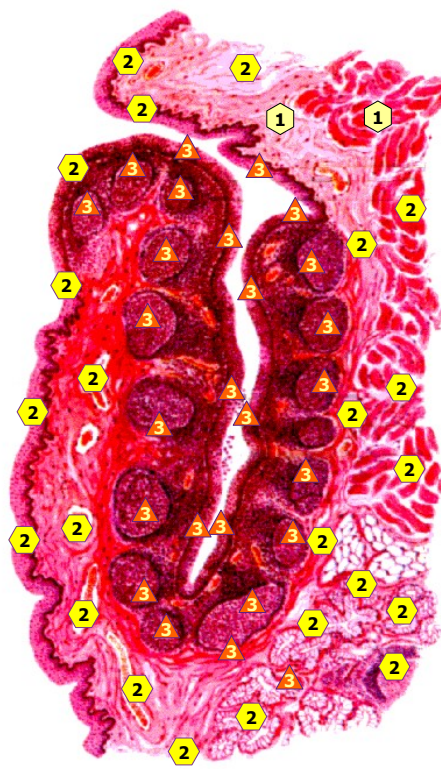
11/09/2024 VEINS OF CRUS, right side



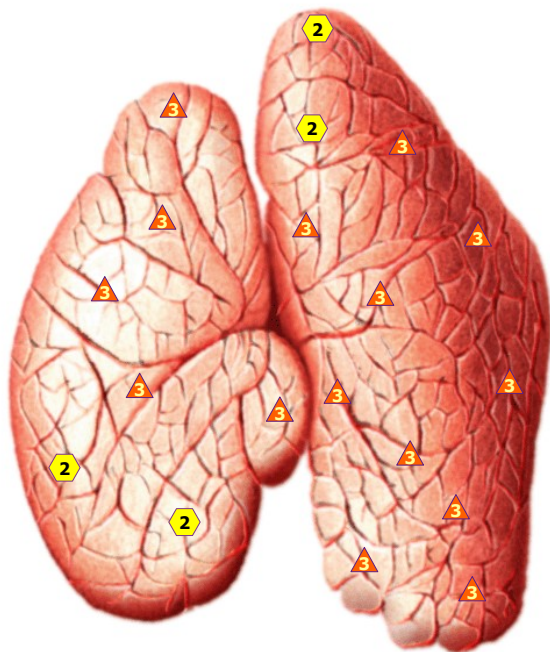
11/09/2024 VEINS OF CRUS, left side




11/09/2024 LYMPHATIC VESSELS OF MEDIASTINUM



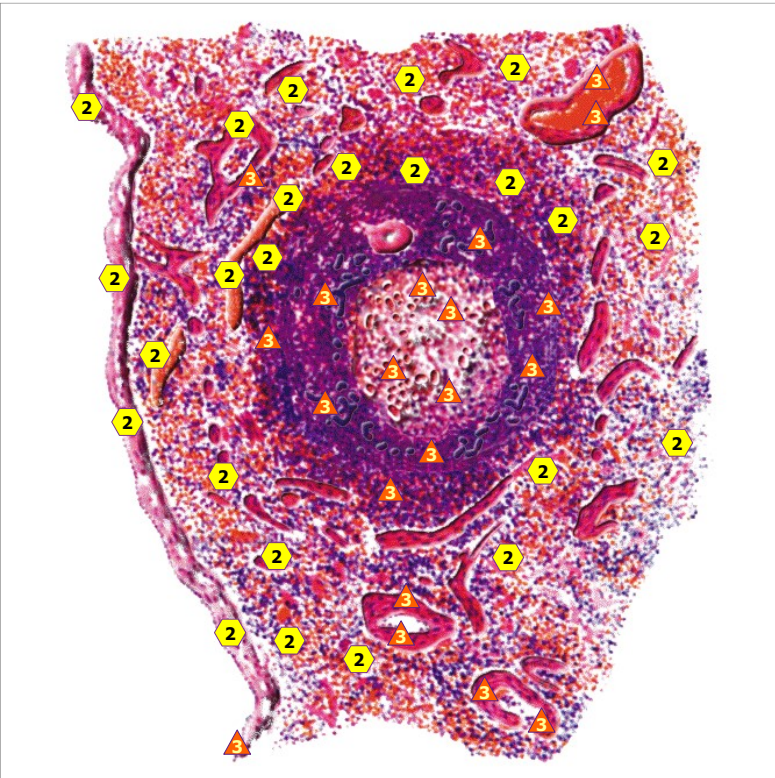
11/09/2024 PALATINE TONSIL




11/09/2024 THYMUS GLAND



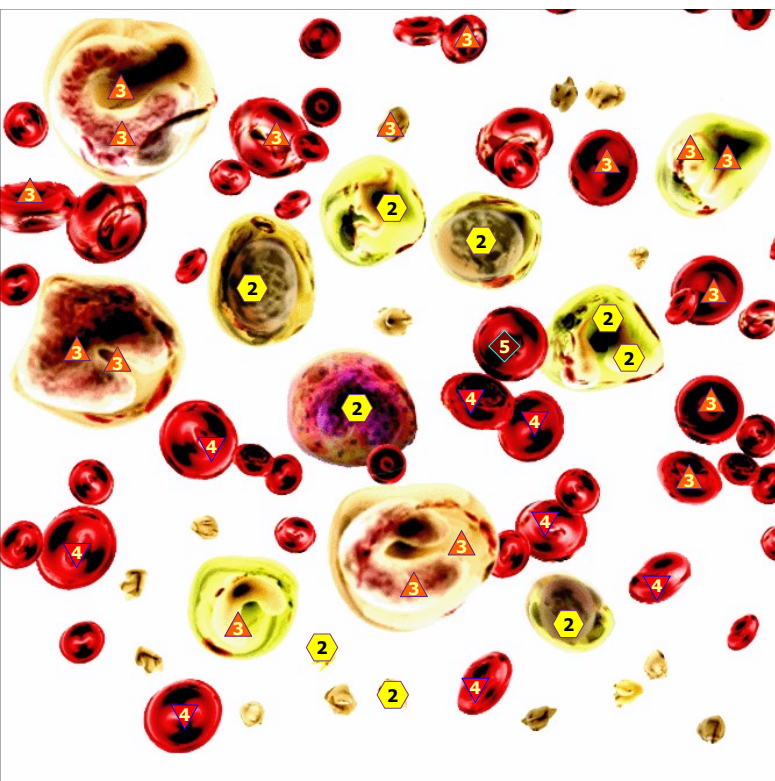
11/09/2024 THYMUS GLAND



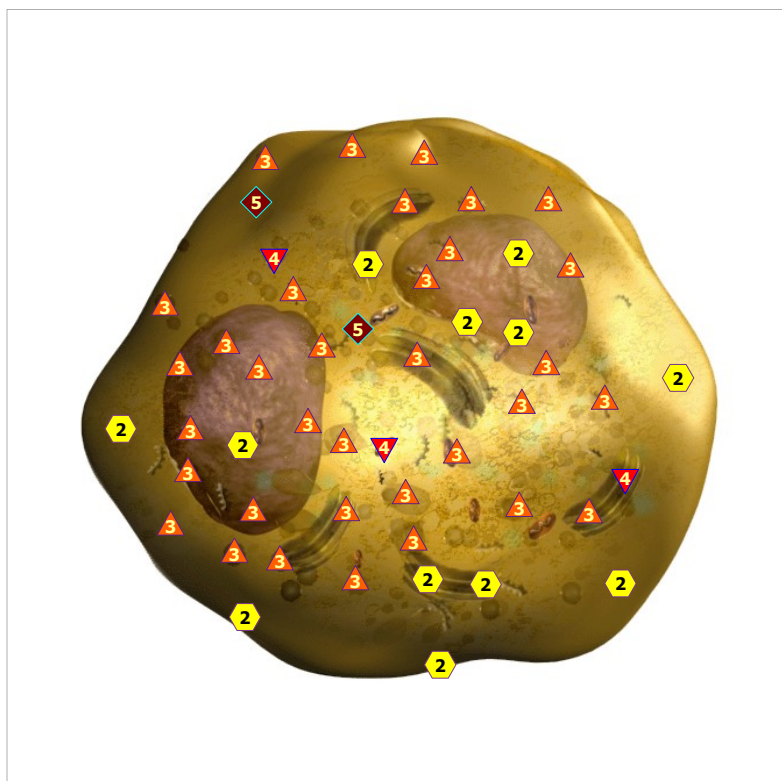
11/09/2024 Spleen # MK



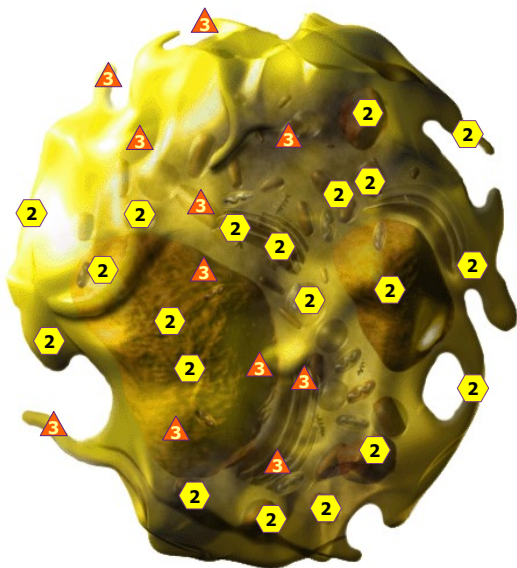
11/09/2024 RED BONE MARROW



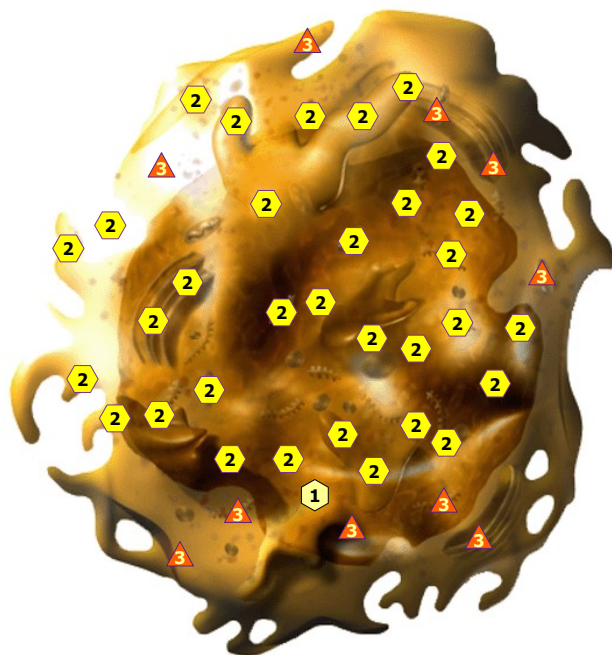
11/09/2024 BLOOD CELLS



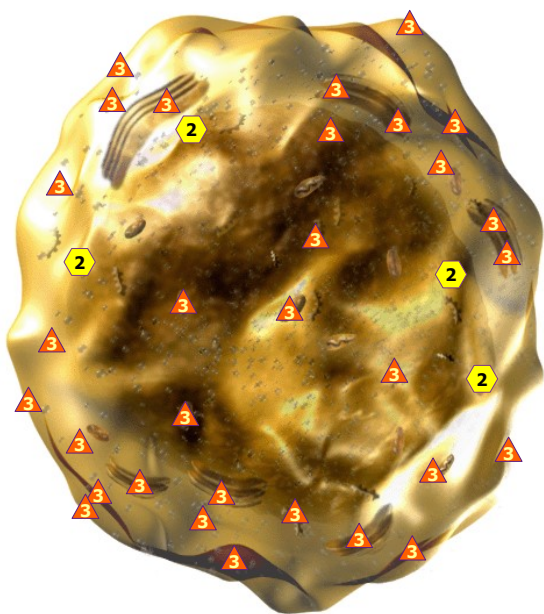
11/09/2024 NEUTROPHIL



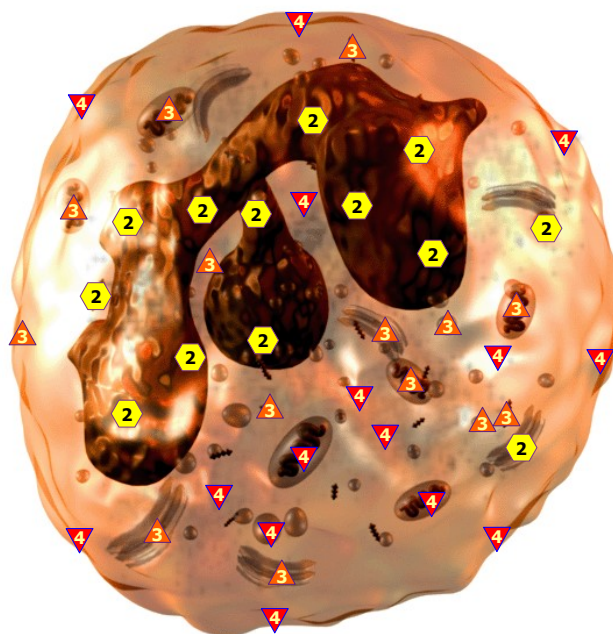
11/09/2024 EOSINOPHIL



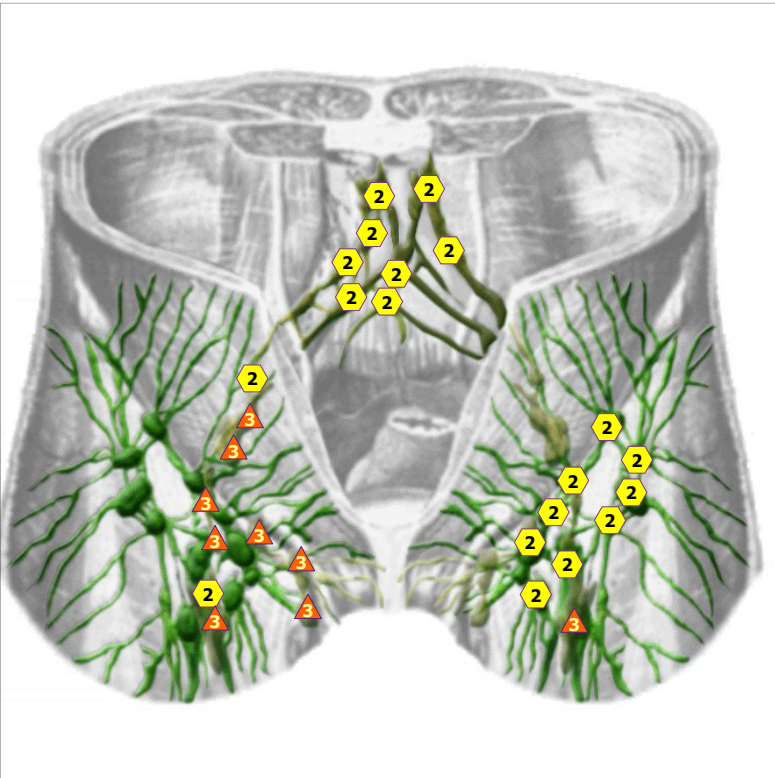
11/09/2024 LYMPHOCYTE



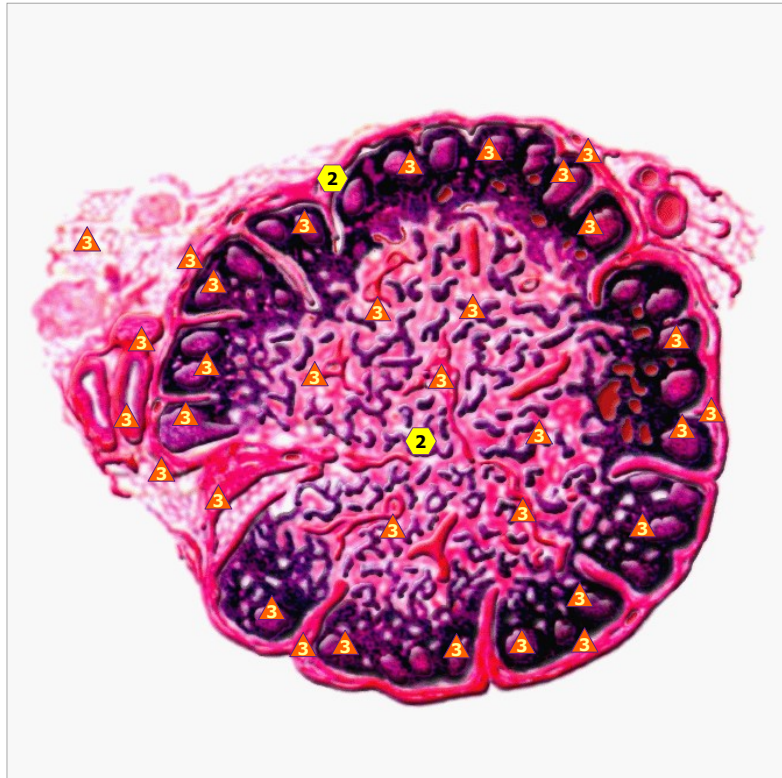11/09/2024 MONOCYTE



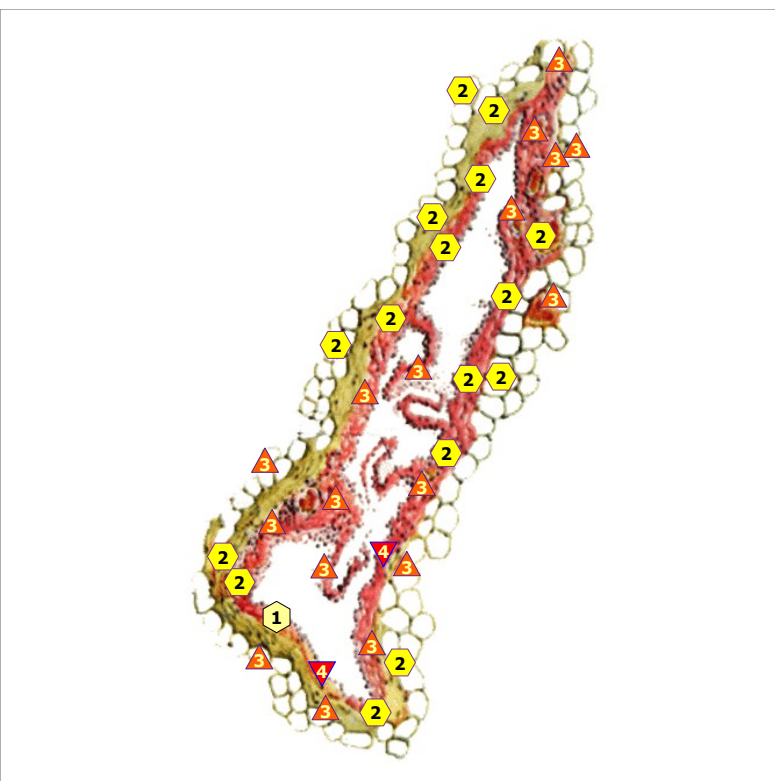
11/09/2024 BASOPHILIC LEUKOCYTE



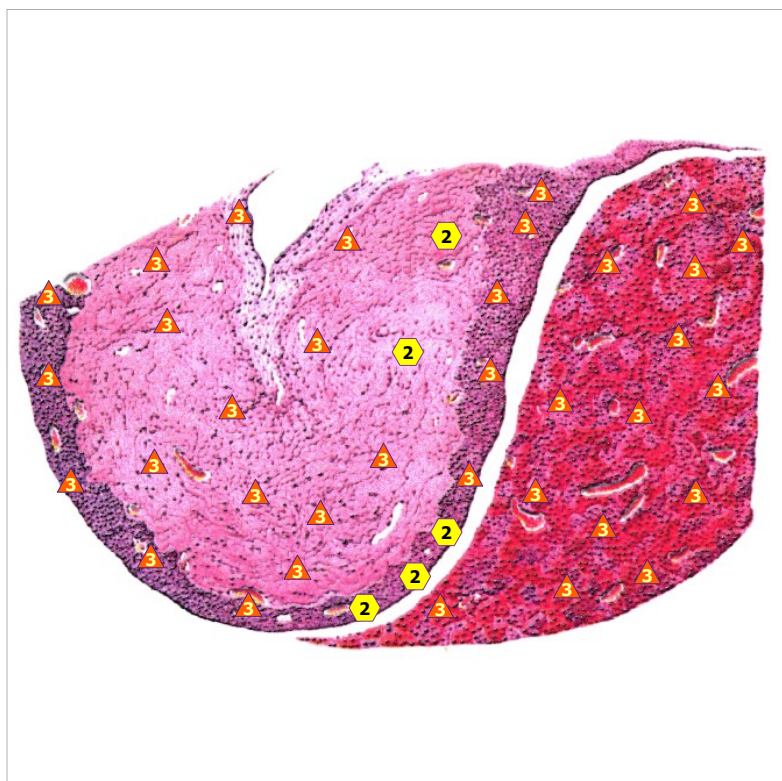
11/09/2024 LYMPHATIC NODES IN INGUINAL PART



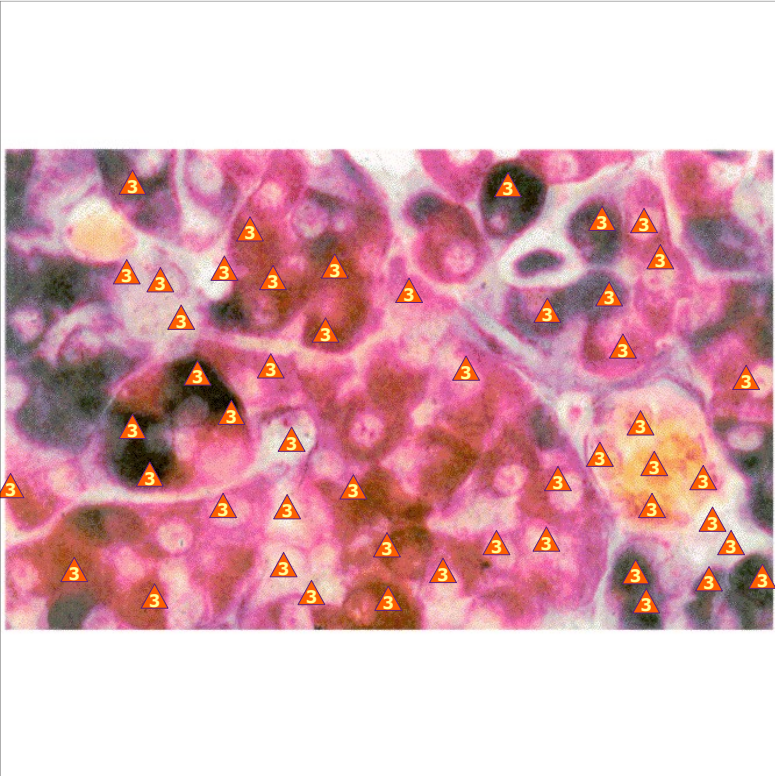
11/09/2024 Lymph node # MK



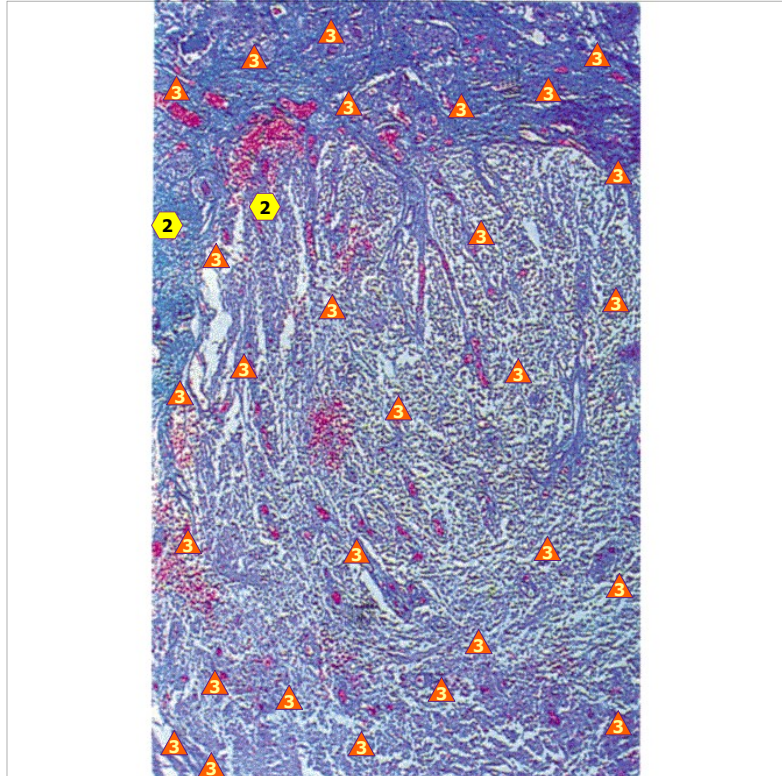
11/09/2024 LYMPHATIC VESSEL



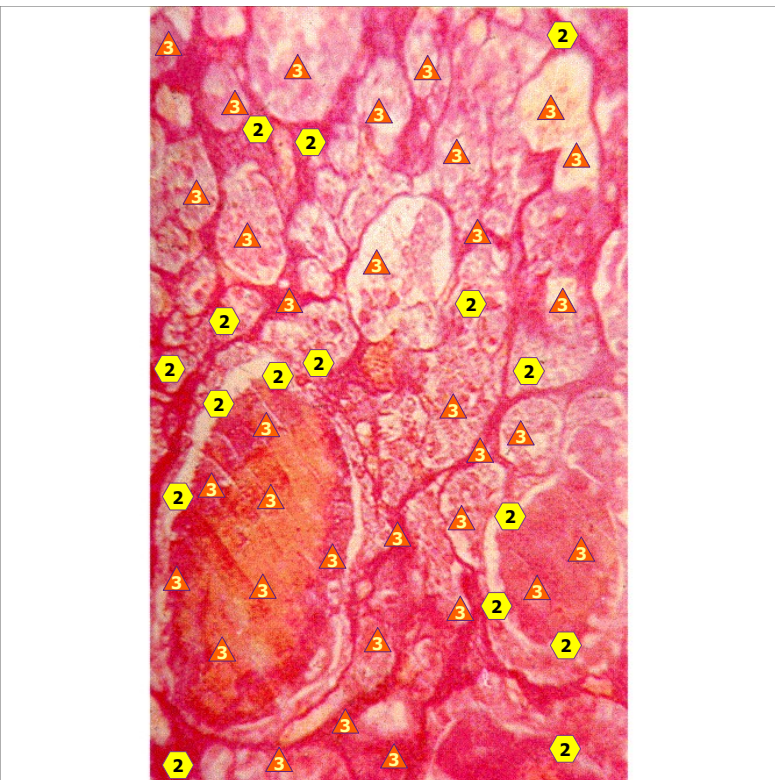
11/09/2024 HYPOPHYSIS



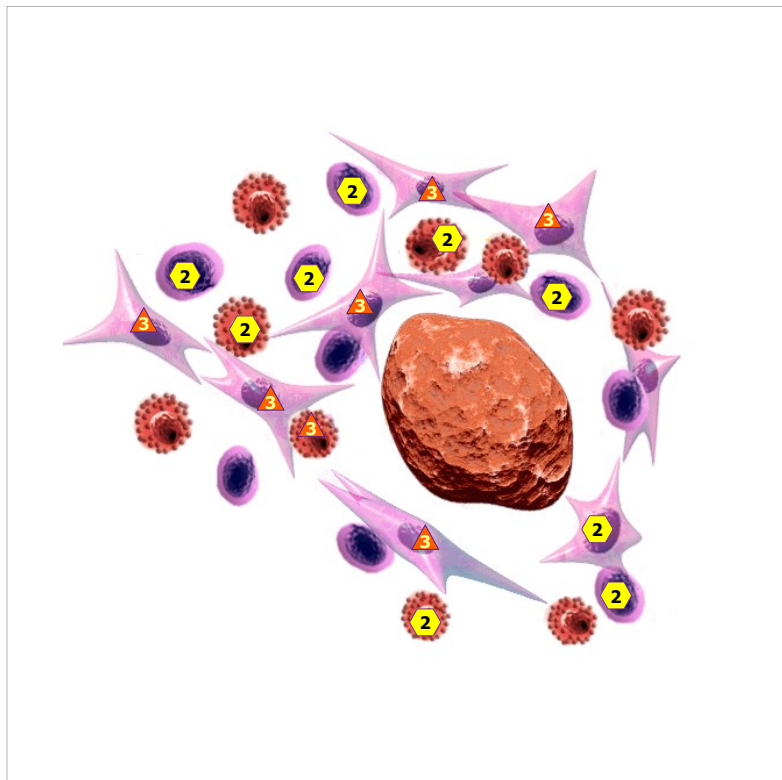
11/09/2024 CELL adenohypophysis # MC



11/09/2024 NEUROHYPOPHYSIS

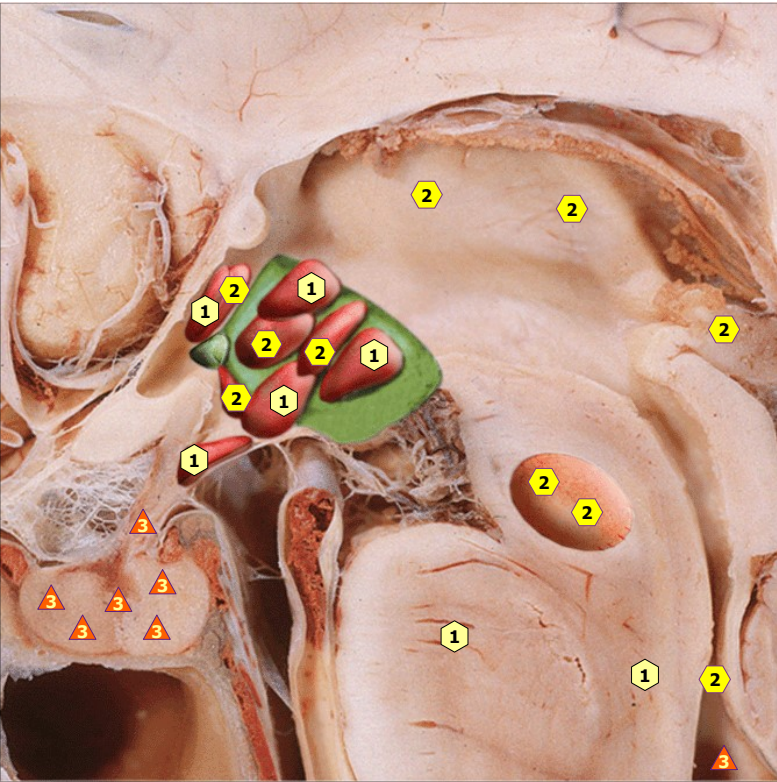


11/09/2024 INTERMEDIAL PART OF HYPOPHYSIS

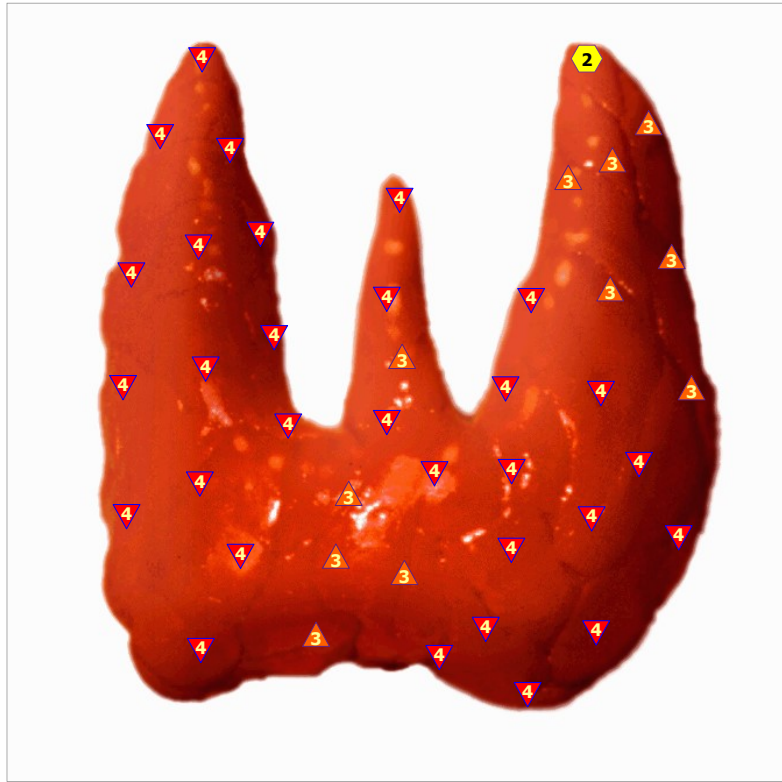

11/09/2024 EPIPHYSIS

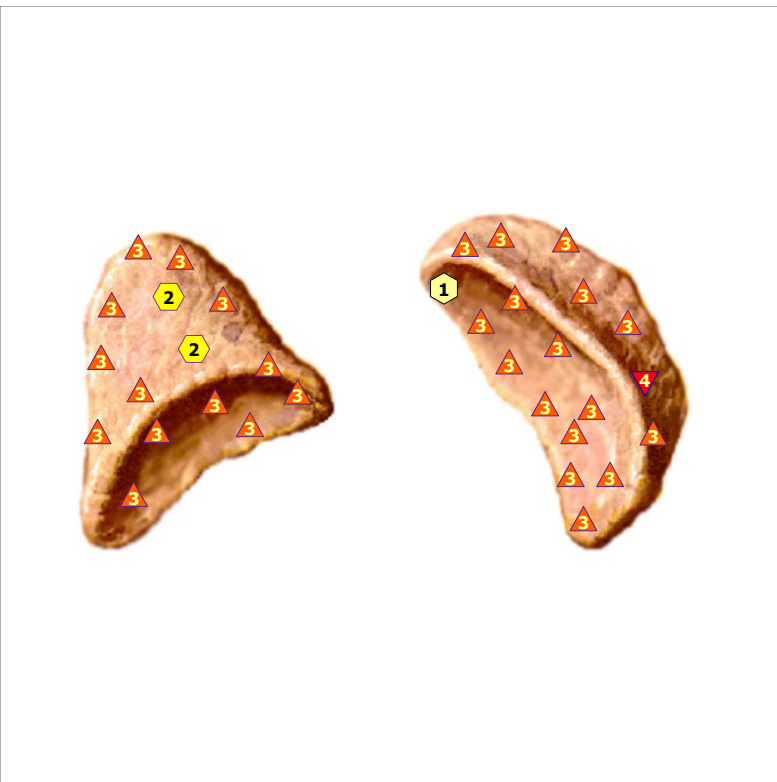




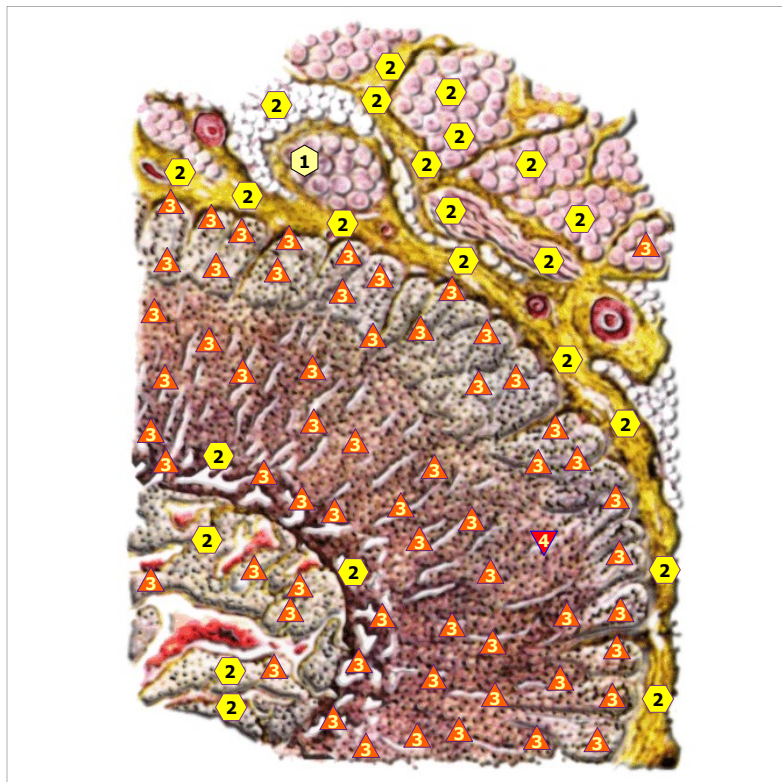
11/09/2024 NUCLEA OF HYPOTHALAMUS



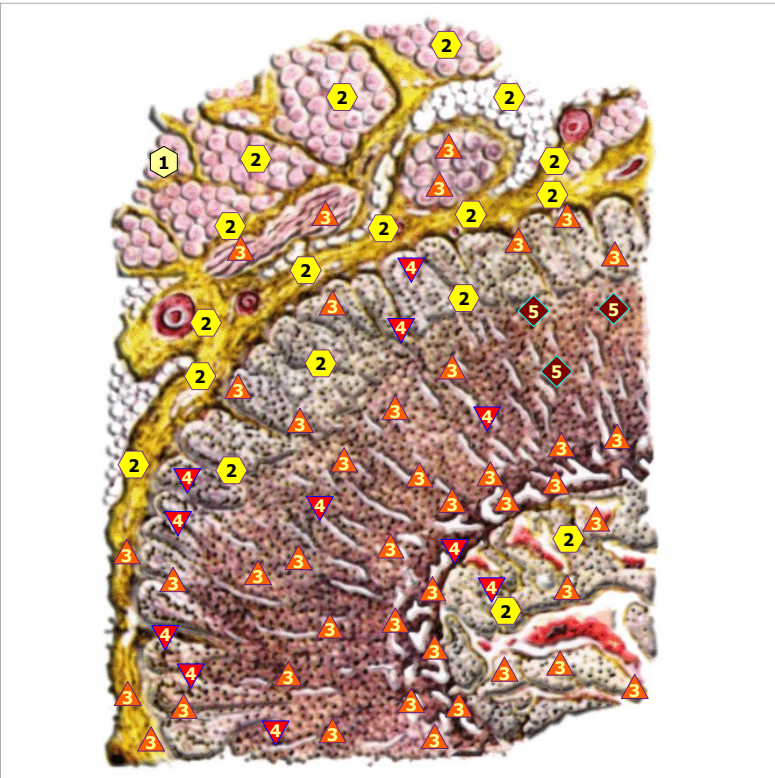
11/09/2024 THYROID GLAND; front view



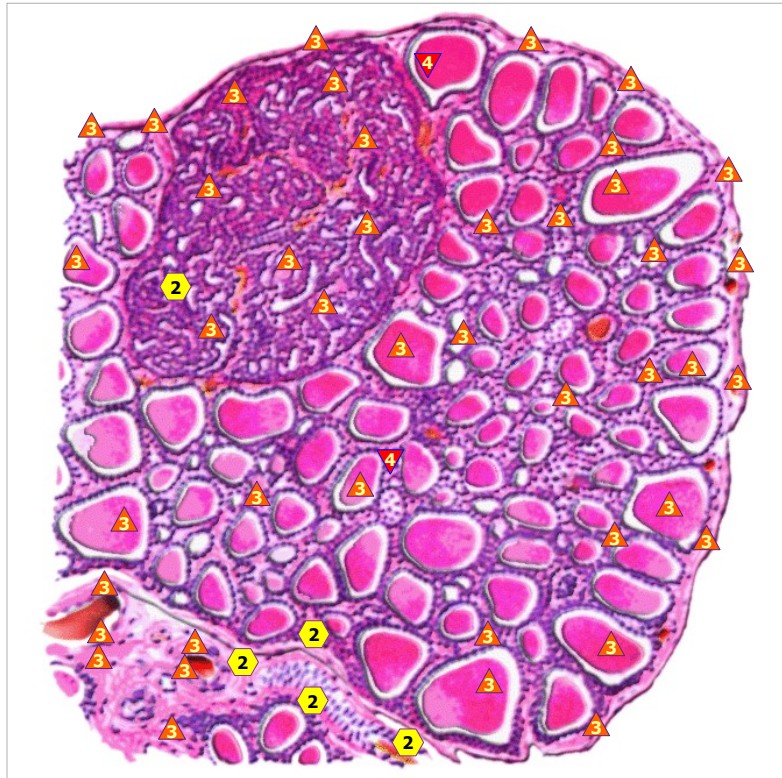
11/09/2024 ADRENALS



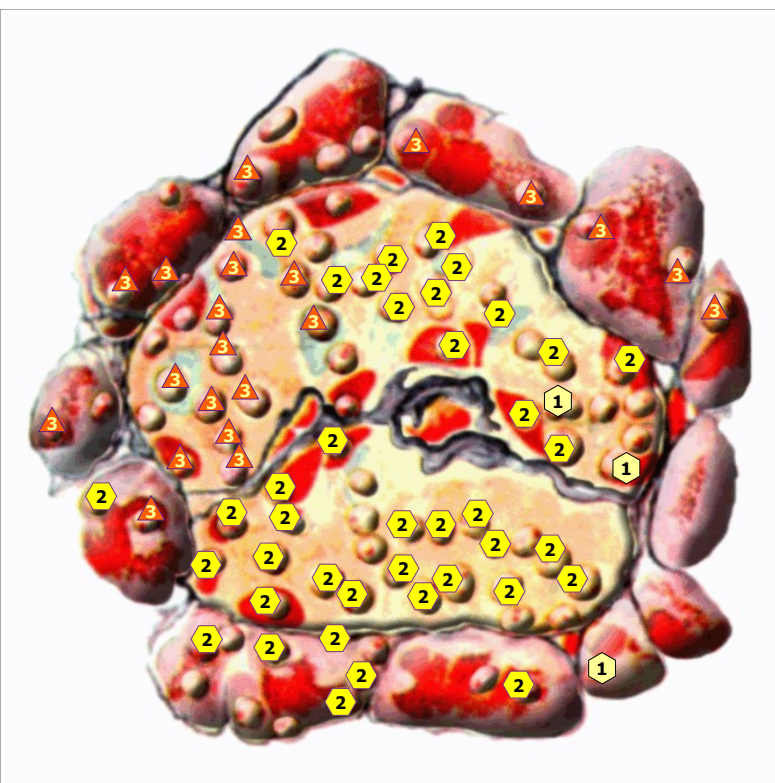
11/09/2024 EPINEPHROS; right view



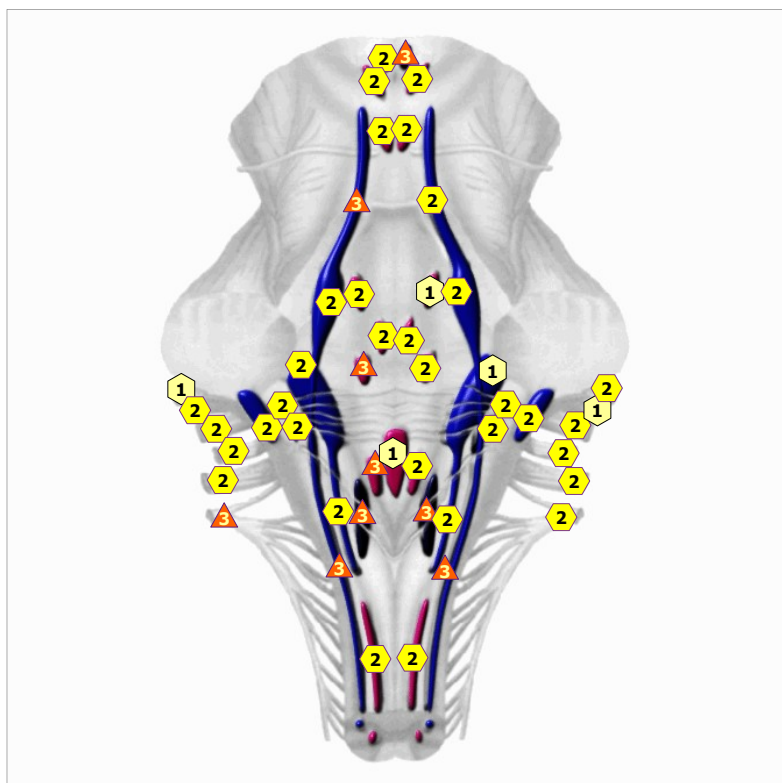
11/09/2024 EPINEPHROS; LEFT VIEW



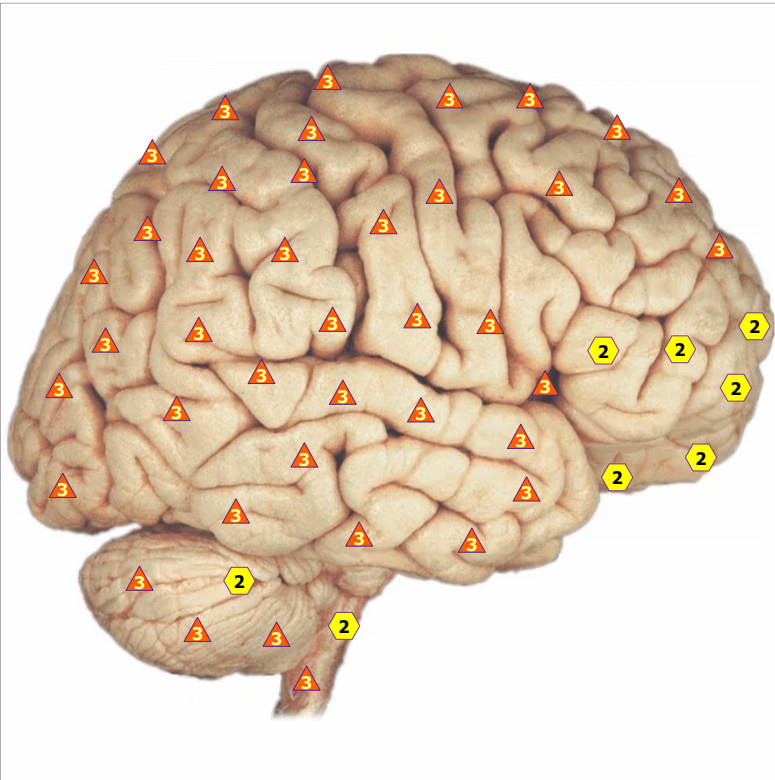
11/09/2024 THYROID AND PARATHYROID GLANDS



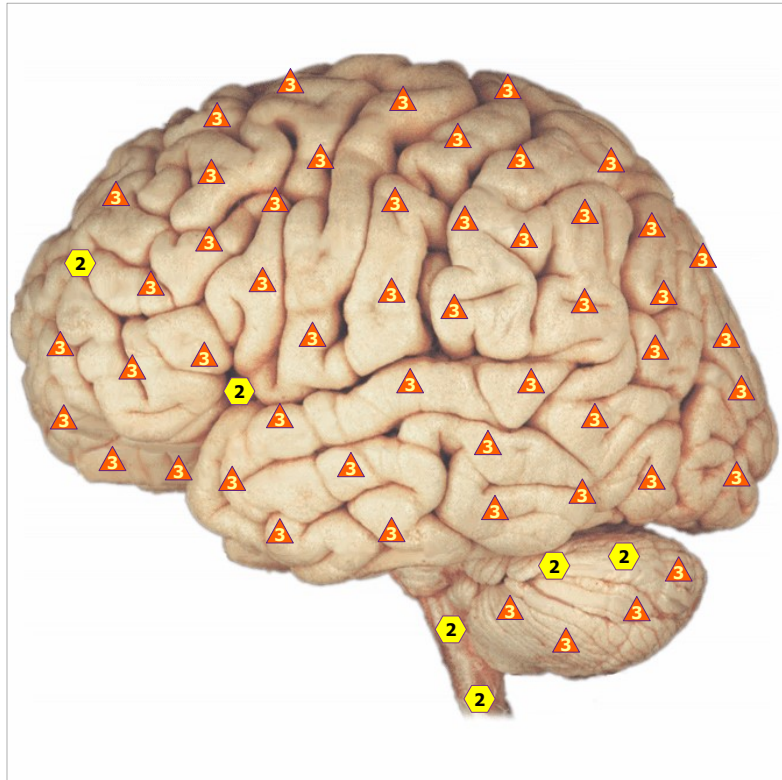
11/09/2024 ISLAND OF LANGERANG



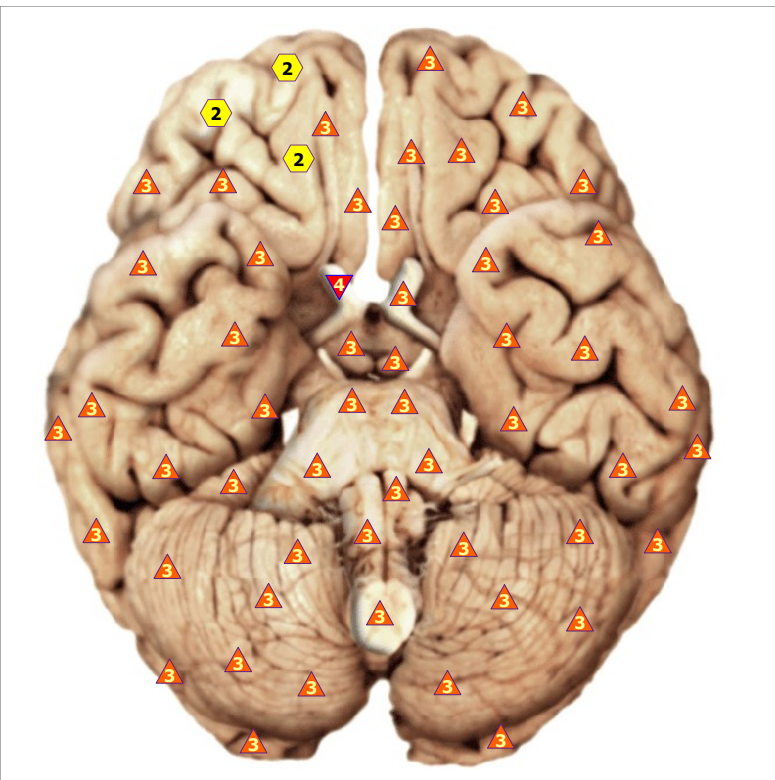
11/09/2024 NUCLEI OF CRANIAL NERVES; view from behind



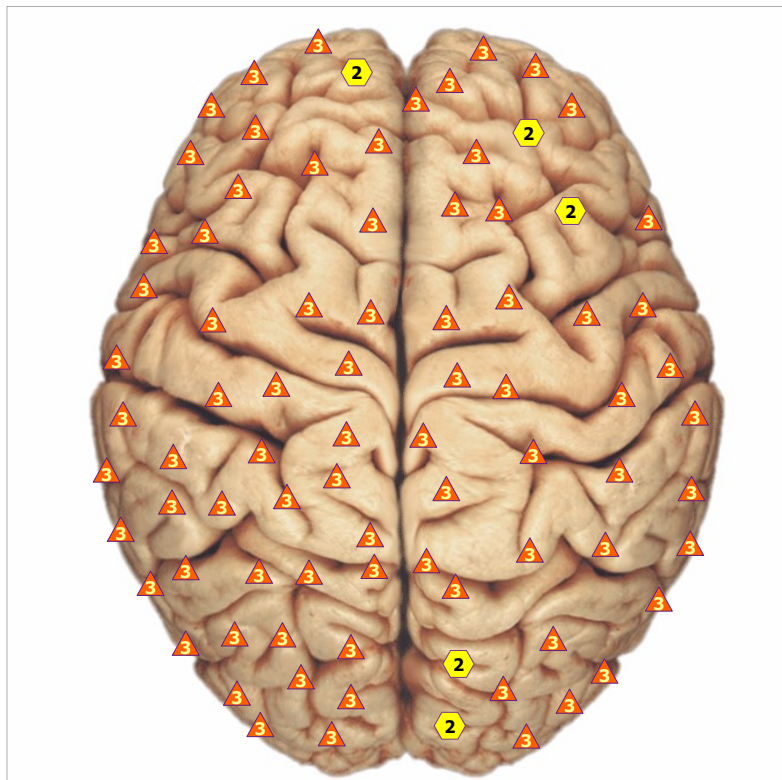
11/09/2024 CEREBRUM, right side



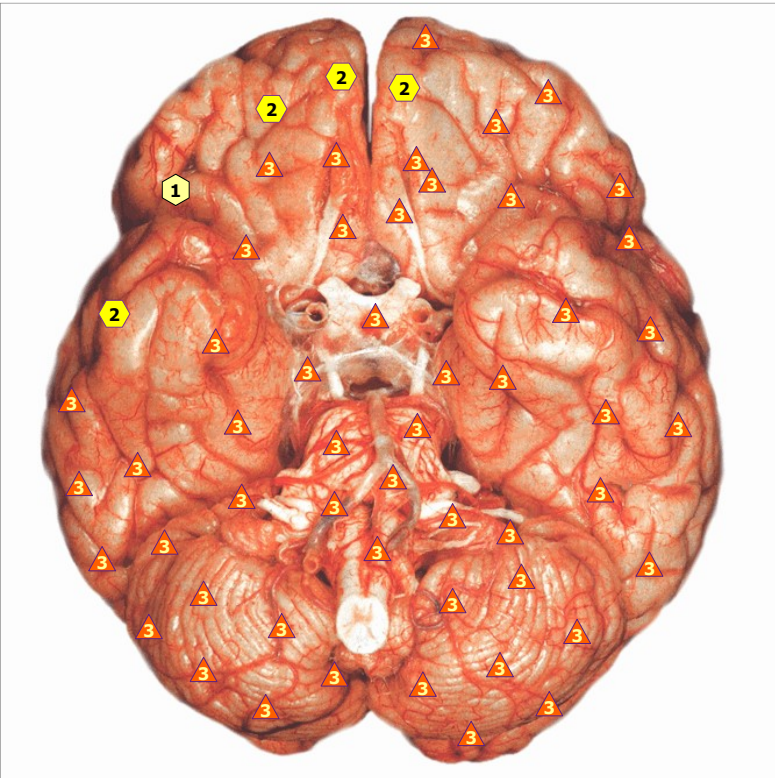
11/09/2024 CEREBRUM, left side



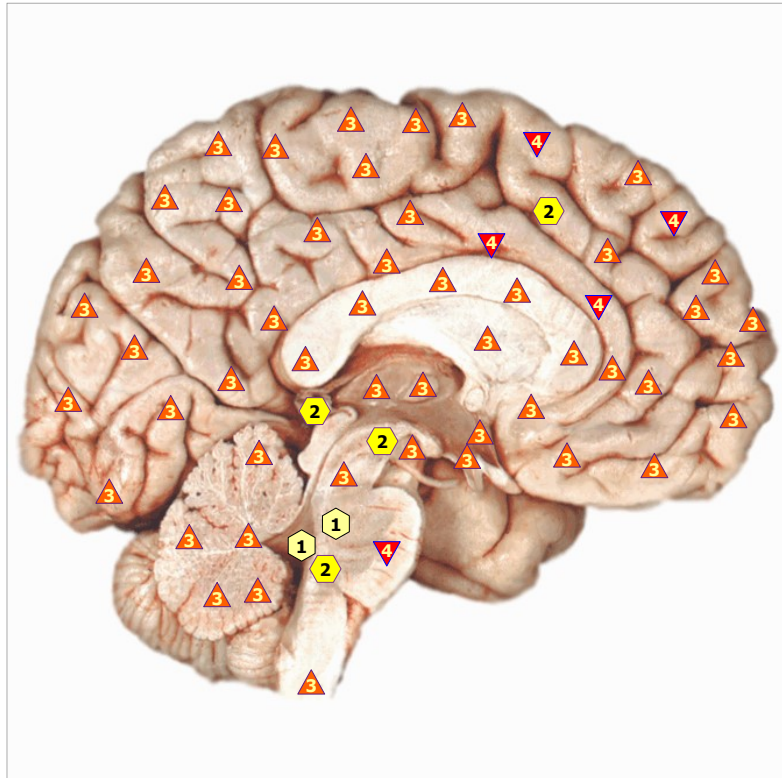
11/09/2024 ENCEPHALON, BUTTOM VIEW, CRANIAL NERVES



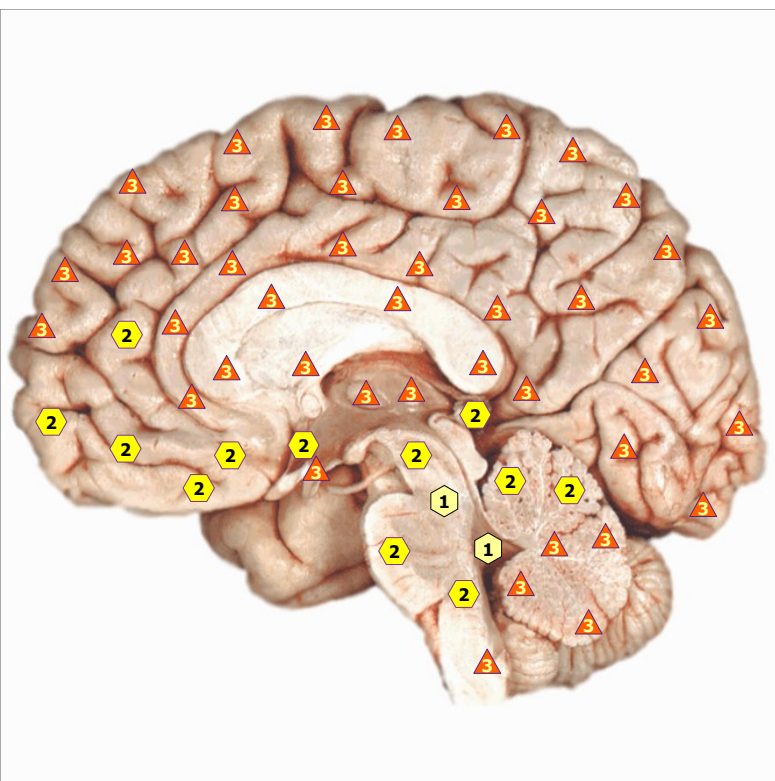
11/09/2024 CEREBRUM, top view



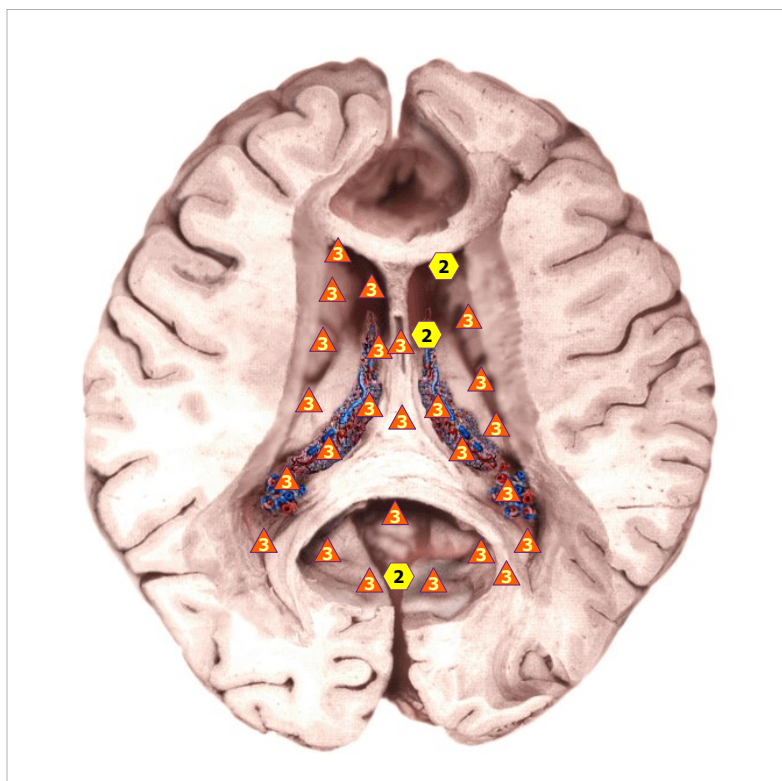
11/09/2024 CEREBRAL PIA MATER



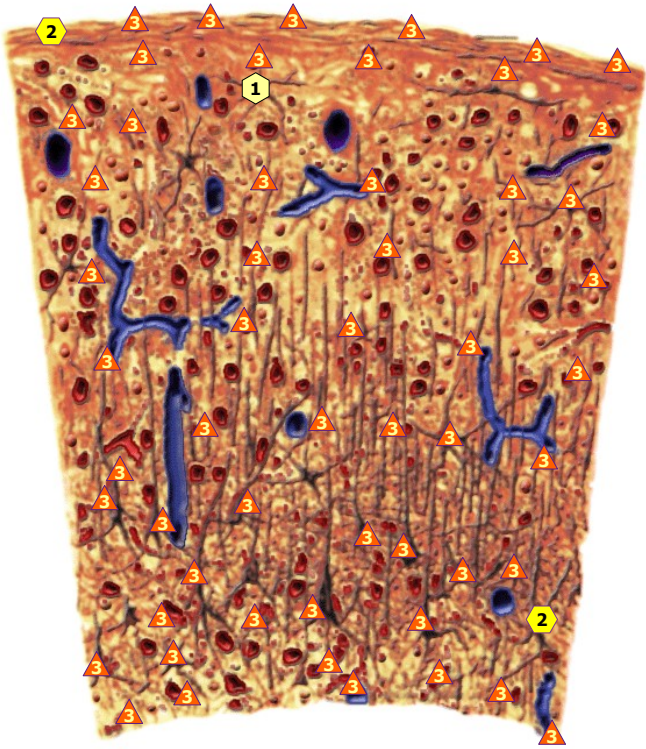
11/09/2024 MEDIAL SURFACE OF CEREBRUM; left side



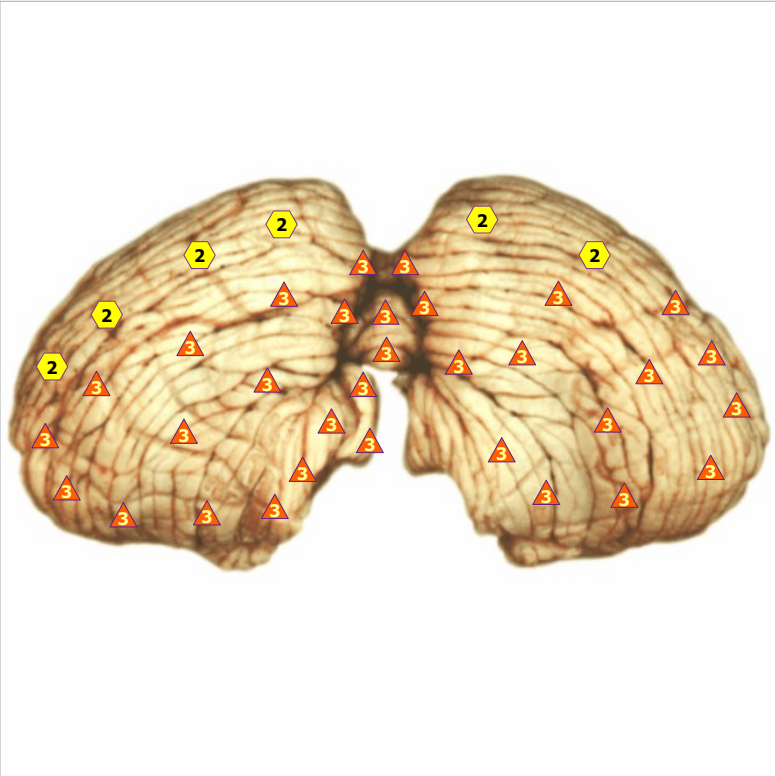
11/09/2024 MEDIAL SURFACE OF CEREBRUM; right view



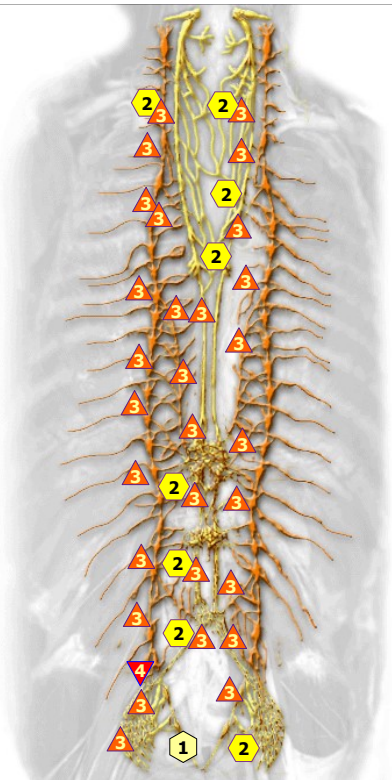
11/09/2024 CEREBRAL VENTRICLES; view from above



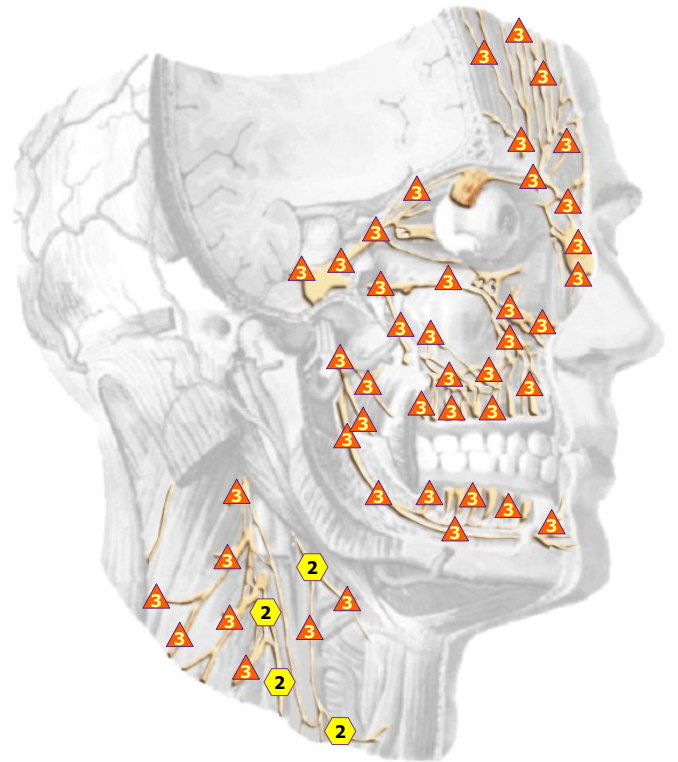
11/09/2024 GRAY MATTER OF CEREBRUM



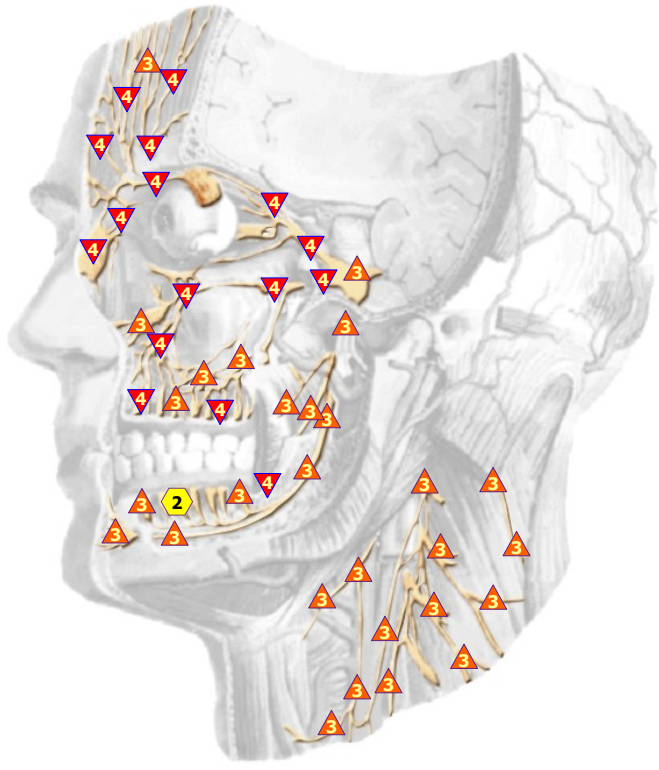
11/09/2024 CEREBELLUM, back and button views



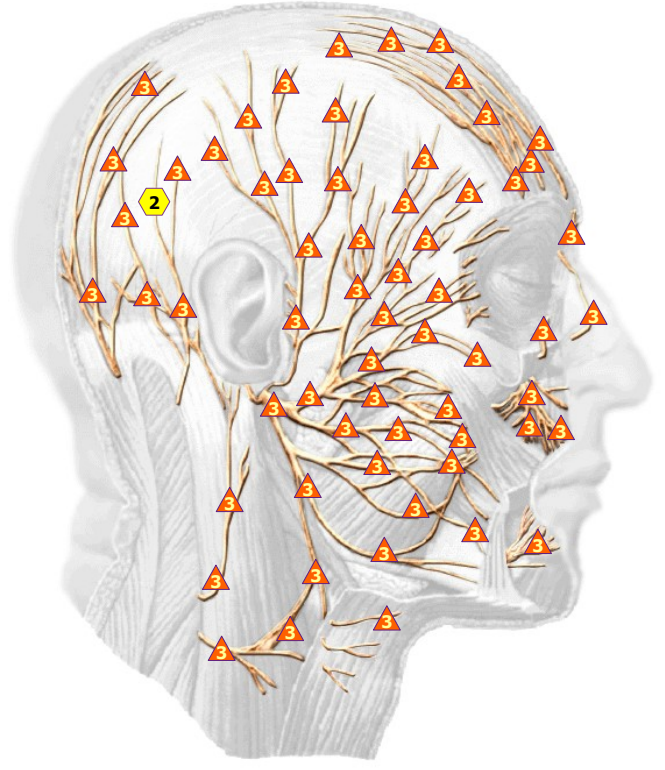
11/09/2024 VEGETATIVE NERVOUS SYSTEM



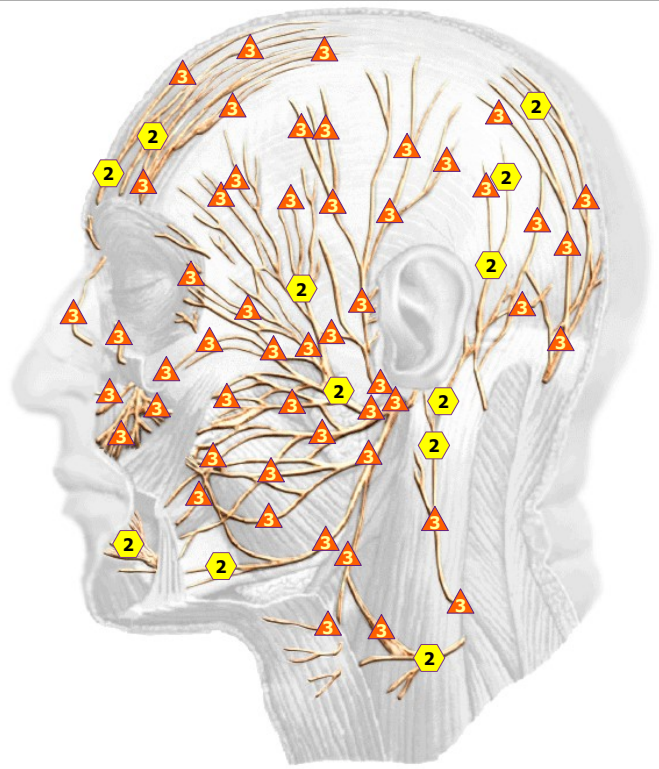
11/09/2024 TRIFACIAL NERVE; right view



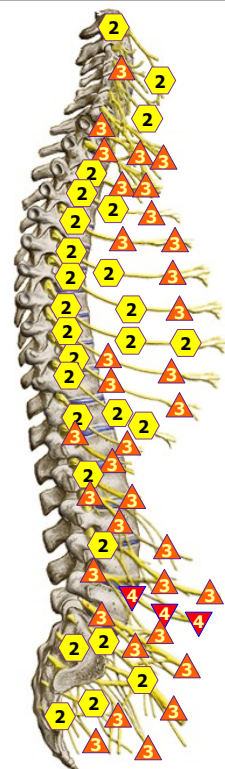
11/09/2024 TRIFACIAL NERVE; left view



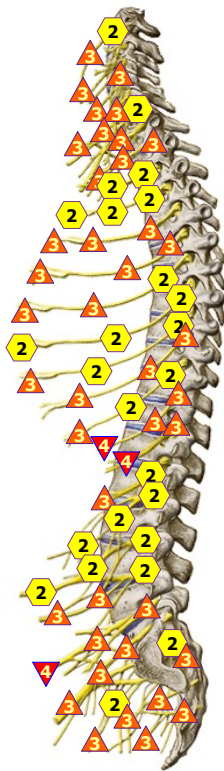
11/09/2024 FACIAL NERVE; right side



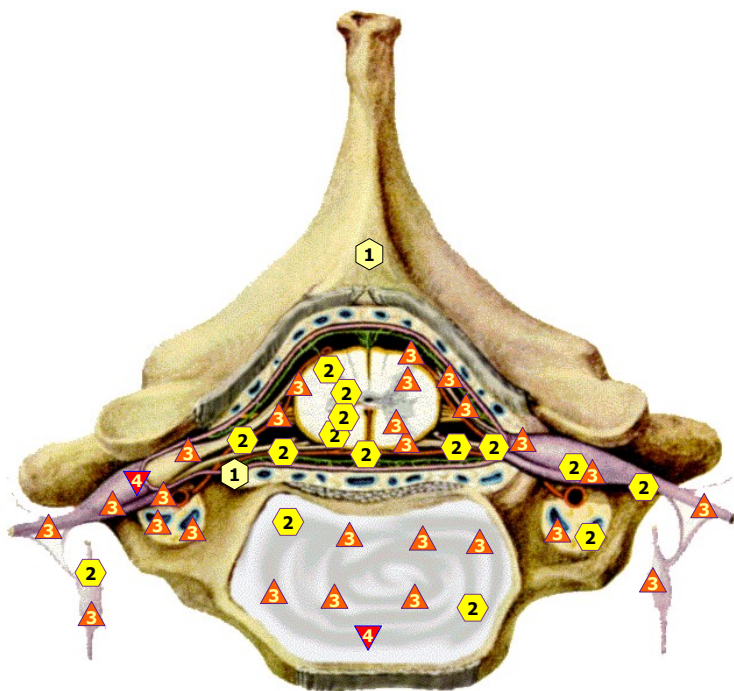
11/09/2024 FACIAL NERVE; left side



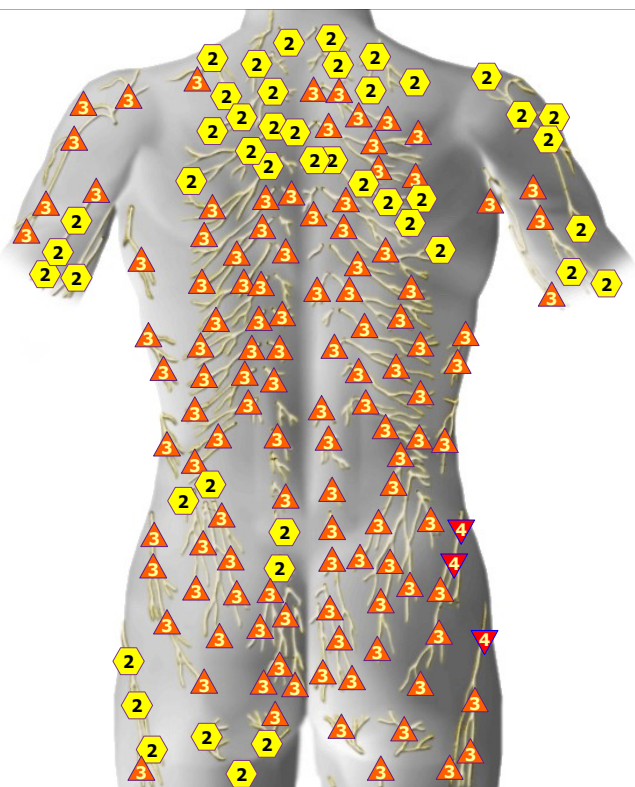
11/09/2024 VERTEBRO-SPINAL NERVES; right view



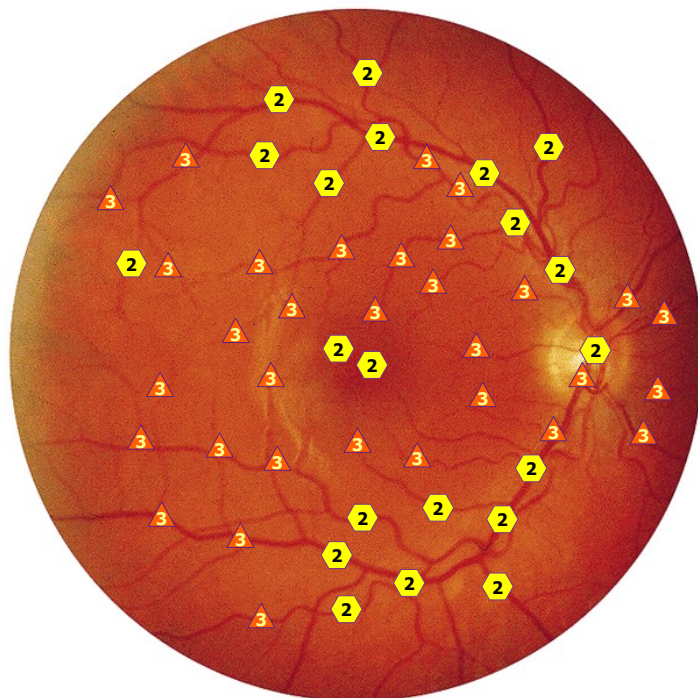
11/09/2024 VERTEBRO-SPINAL NERVES; left view



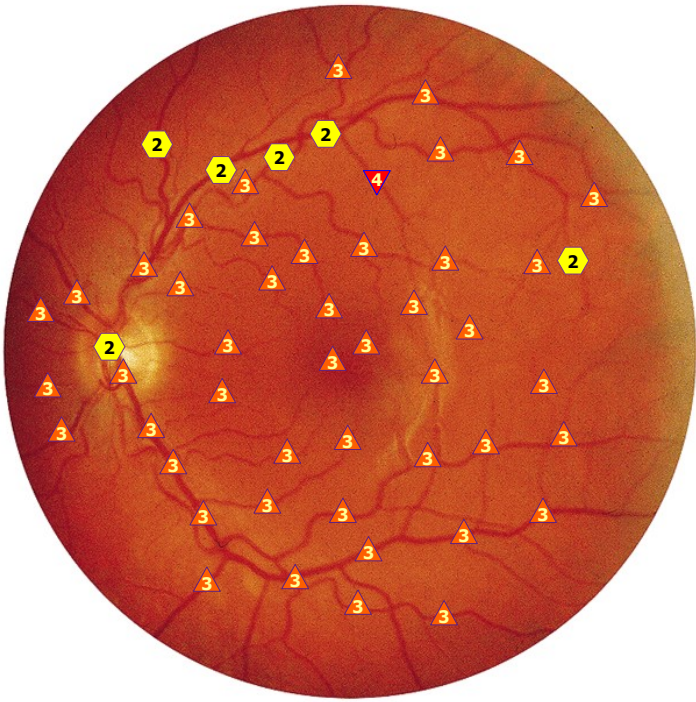
11/09/2024 MEMBRANES OF THE SPINAL MARROW



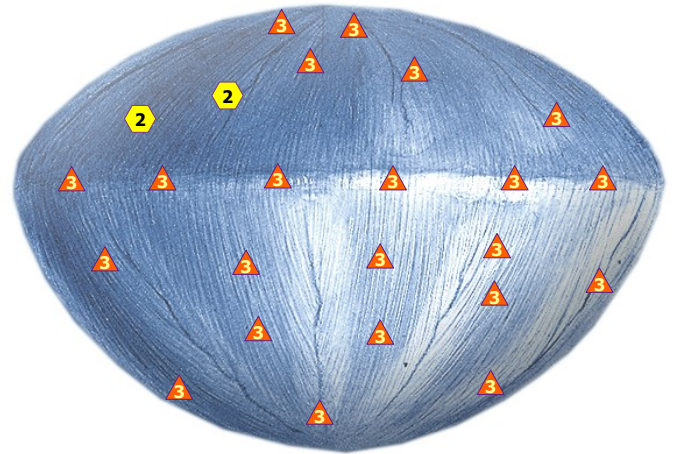
11/09/2024 NERVES OF BACK



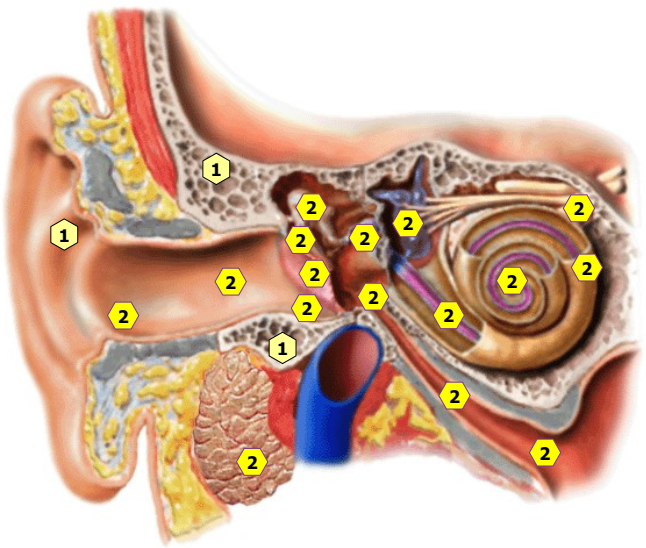
11/09/2024 EYEGROUND; from the right



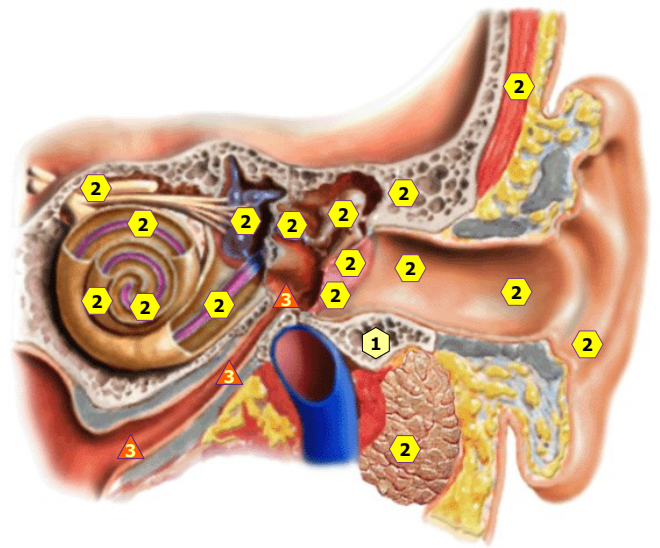
11/09/2024 EYEGROUND; from the left



11/09/2024 Crystalline lens of the eye

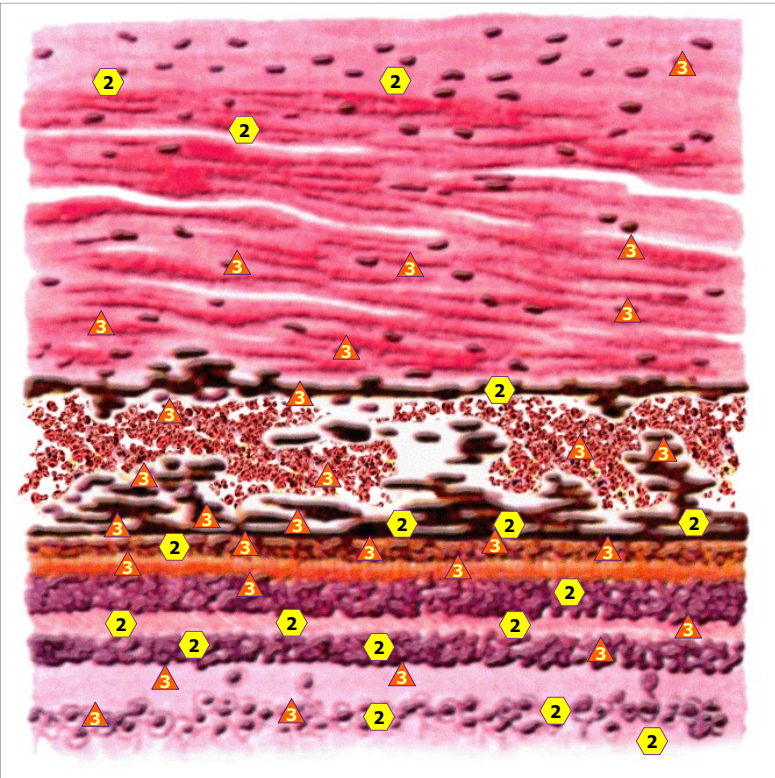


11/09/2024 ACOUSTIC ORGAN; RIGHT

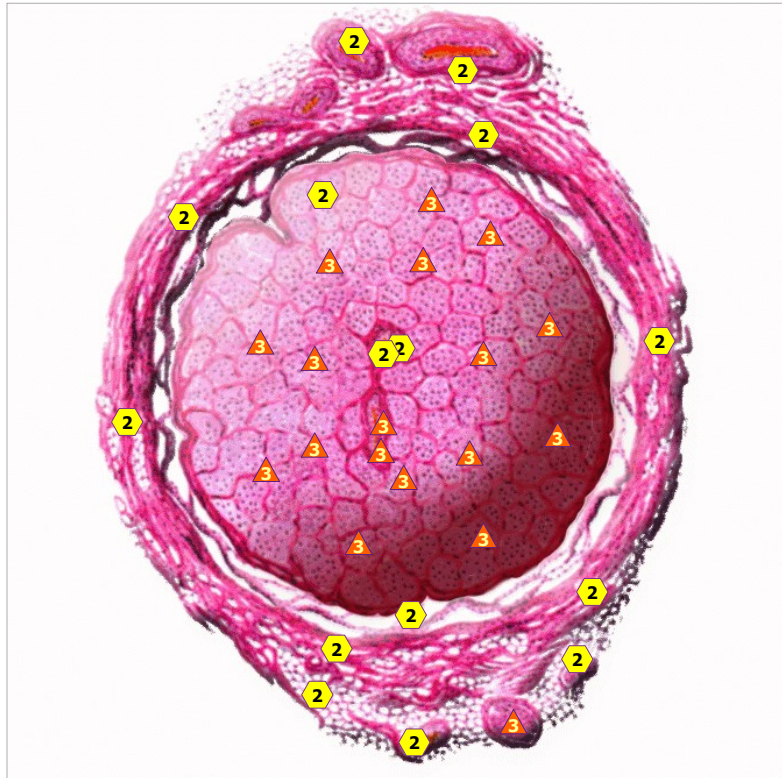


11/09/2024 ACOUSTIC ORGAN; LEFT

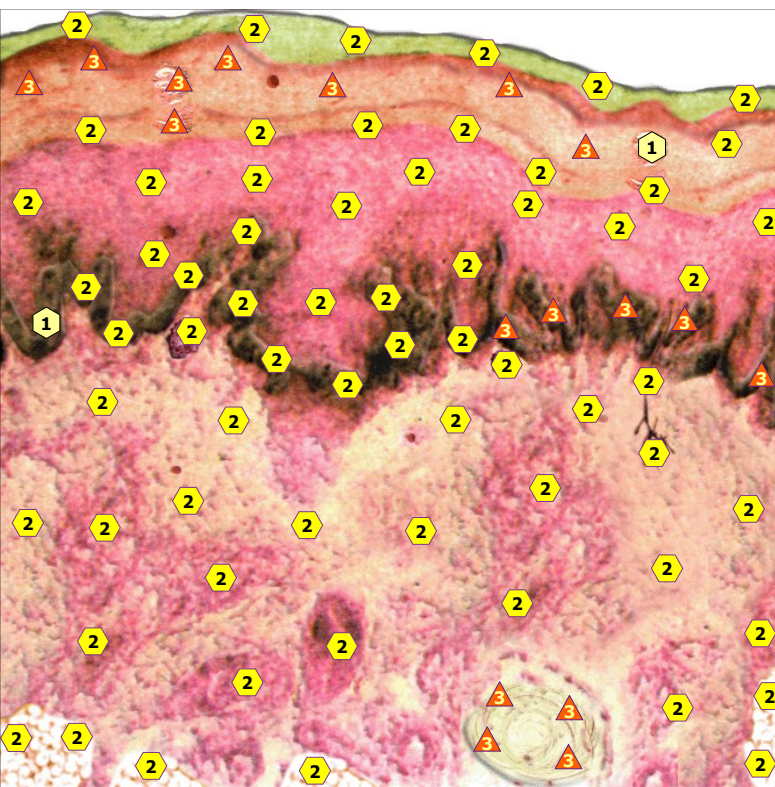




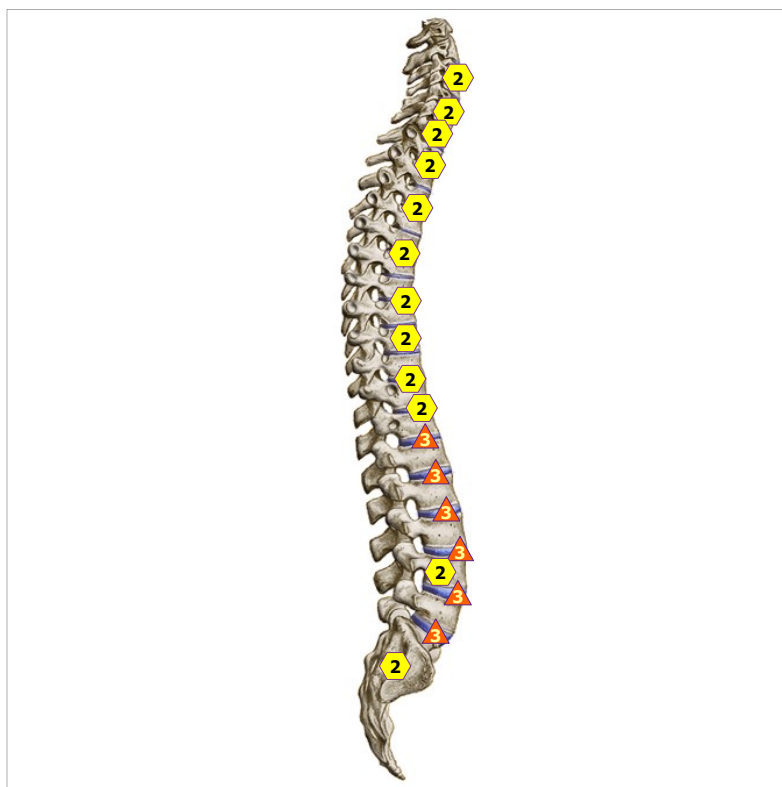11/09/2024 SECTION OF EYEBALL WALL



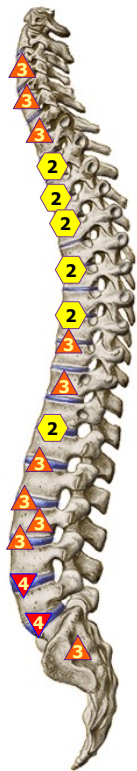
11/09/2024 TRANSVERSAL SECTION OF OPTIC NERVE



11/09/2024 Section of skin MC #



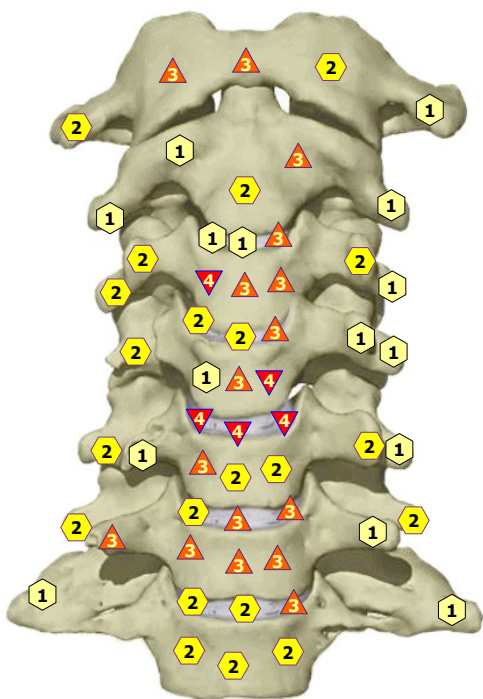
11/09/2024 RACHIS, right lateral view



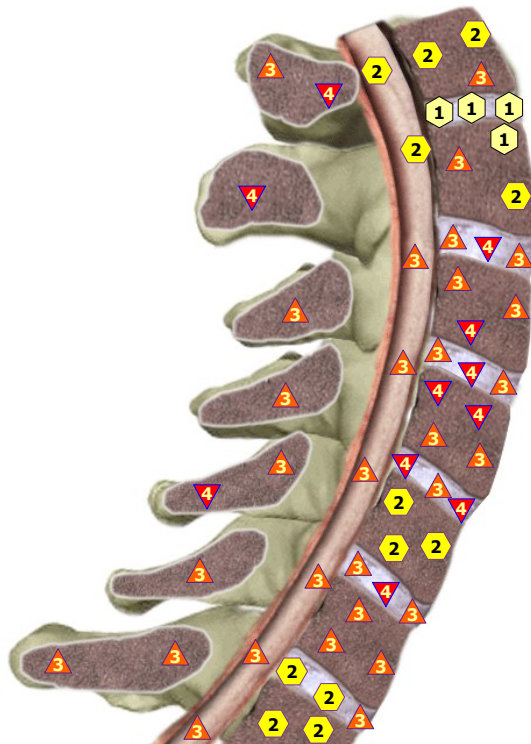
11/09/2024 RACHIS, left lateral view



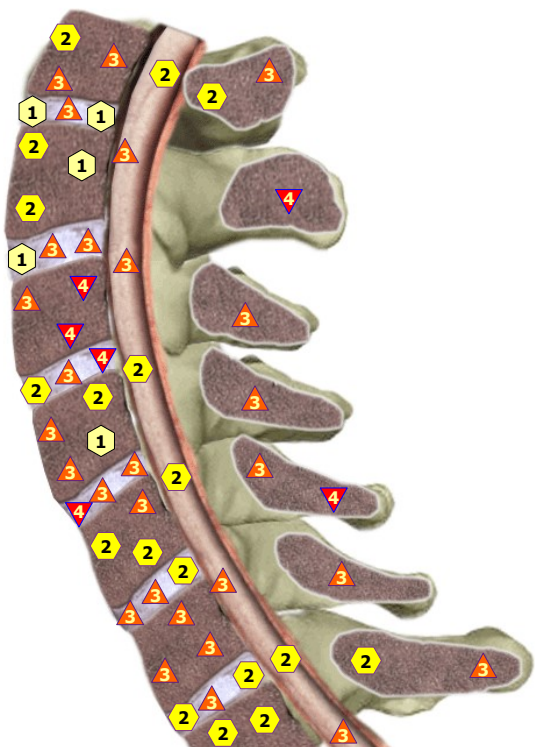
11/09/2024 RACHIS, front view



11/09/2024 CERVICAL SECTOR OF VERTABRAL COLUMN; front view



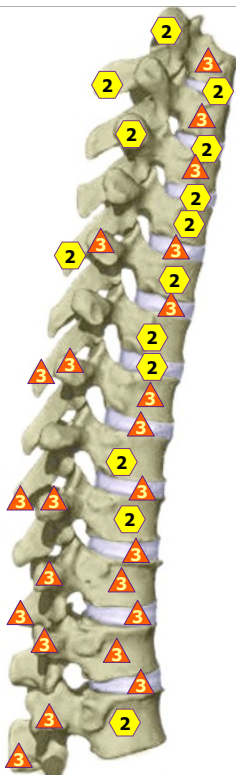
11/09/2024 MEDIAN SAGITTAL SECTION OF CERVICAL VERTEBRAE; right view



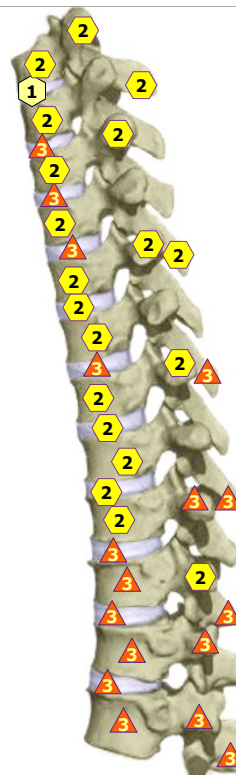
11/09/2024 MEDIAN SAGITTAL SECTION OF CERVICAL VERTEBRAE; left view



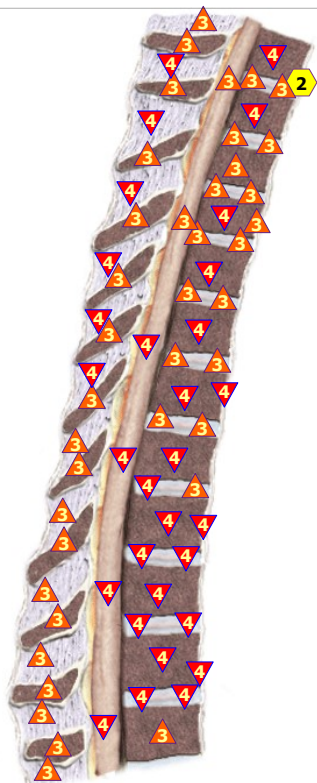11/09/2024 THORACAL SECTOR OF VERTEBRAL COLUMN; front view



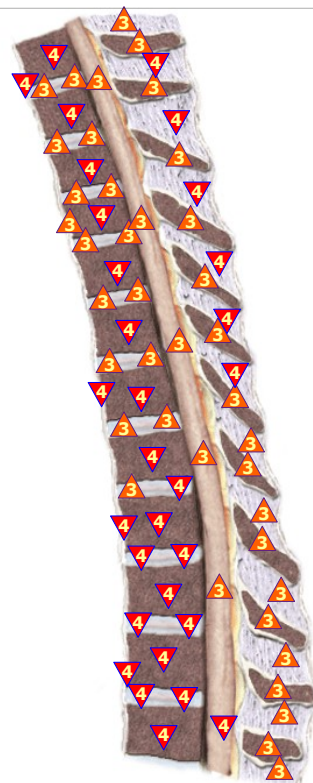11/09/2024 THORACAL SECTOR OF VERTEBRAL COLUMN; right side view



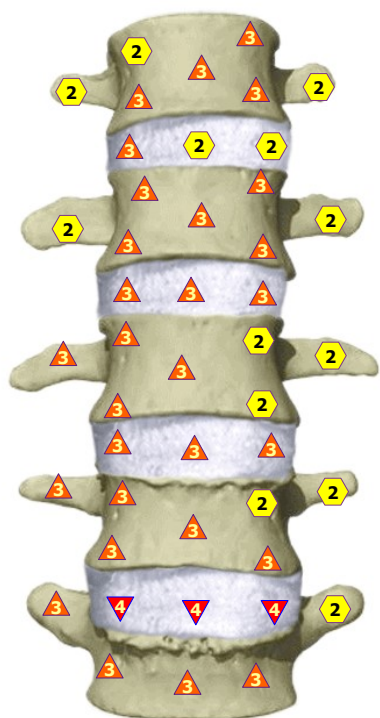
11/09/2024 THORACAL SECTOR OF VERTEBRAL COLUMN; left side view



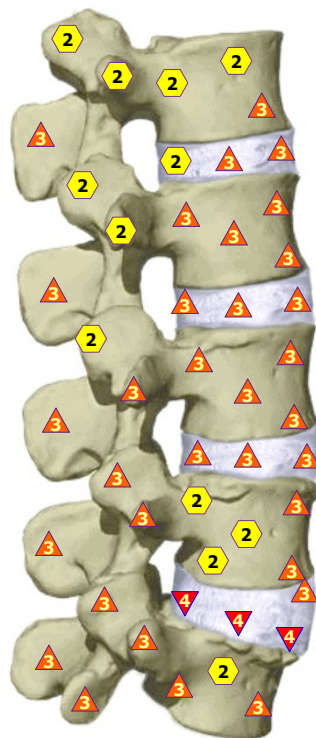
11/09/2024 MEDIAN SAGITTAL SECTION OF THORACIC VERTABRAE; right view



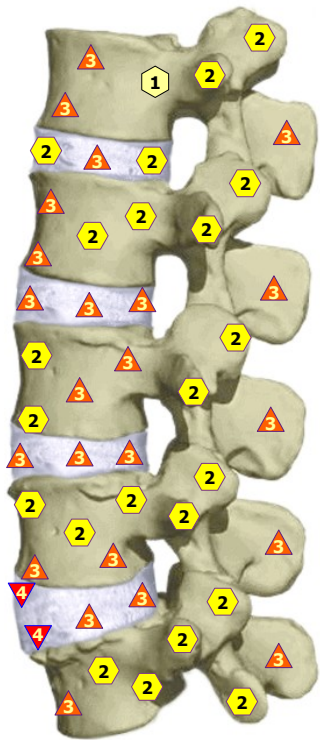
11/09/2024 MEDIAN SAGITTAL SECTION OF THORACIC VERTABRAE; left view



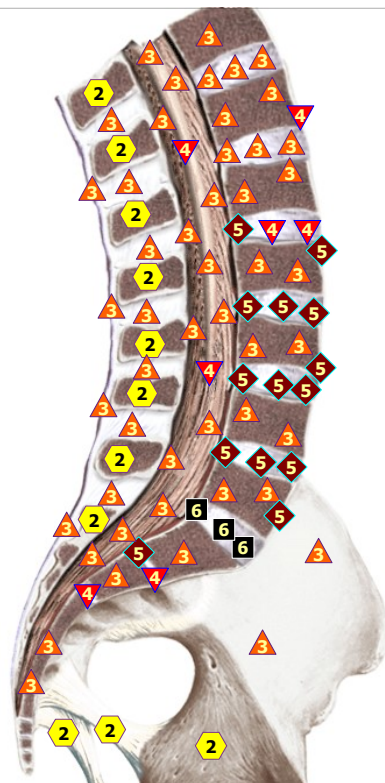
11/09/2024 LUMBAR SECTOR OF VERTEBRAL COLUMN; front view




11/09/2024 LUMBAR SECTOR OF VERTEBRAL COLUMN; right side view



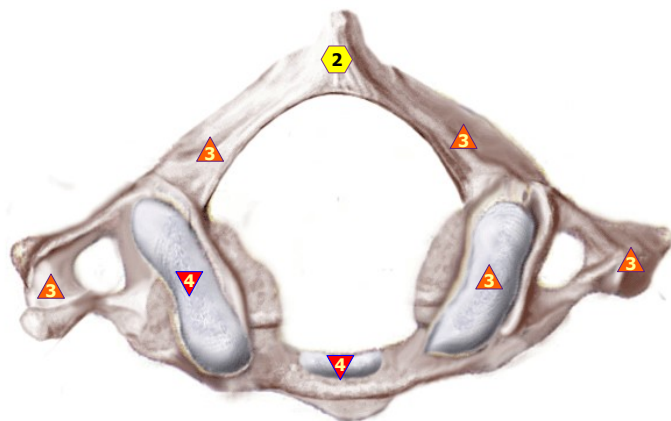
11/09/2024 LUMBAR SECTOR OF VERTEBRAL COLUMN; left side view



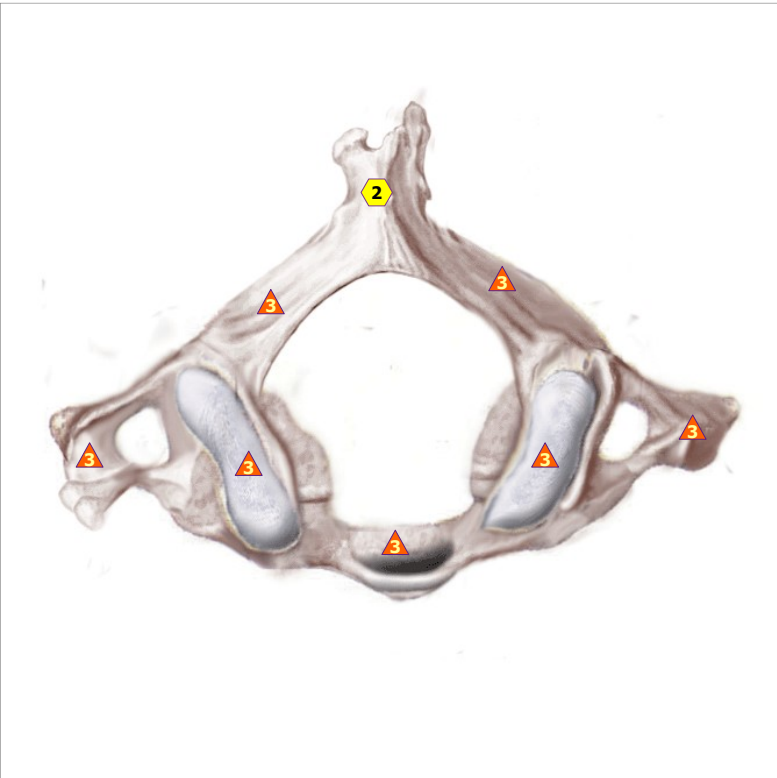
11/09/2024 MEDIAN SAGITTAL SECTION OF INFERIOR SECTOR OF VERTEBRAL COLUMN; right view



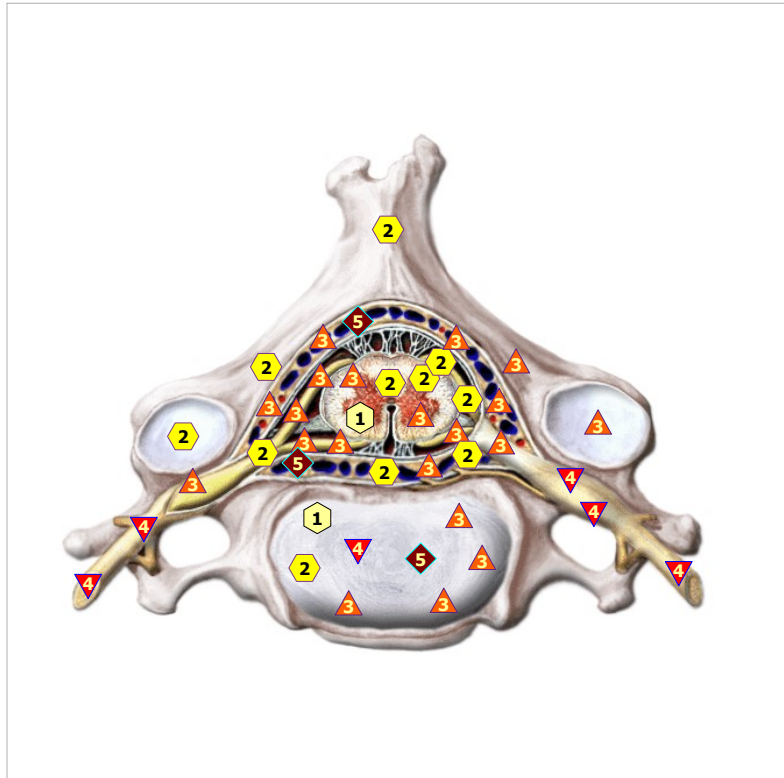11/09/2024 MEDIAN SAGITTAL SECTION OF INFERIOR SECTOR OF VERTEBRAL COLUMN; left view



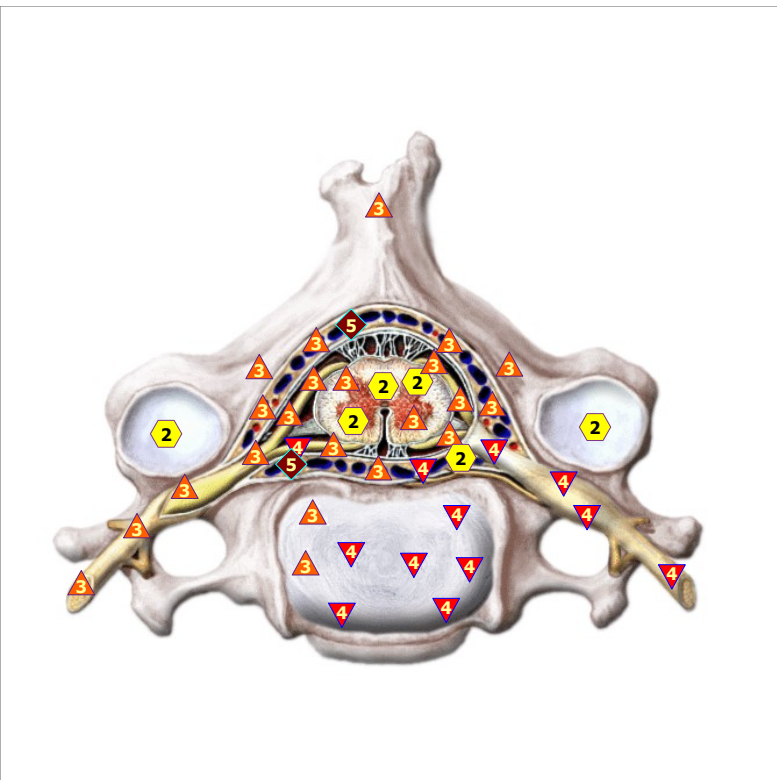11/09/2024 FIRST NECK-BONE



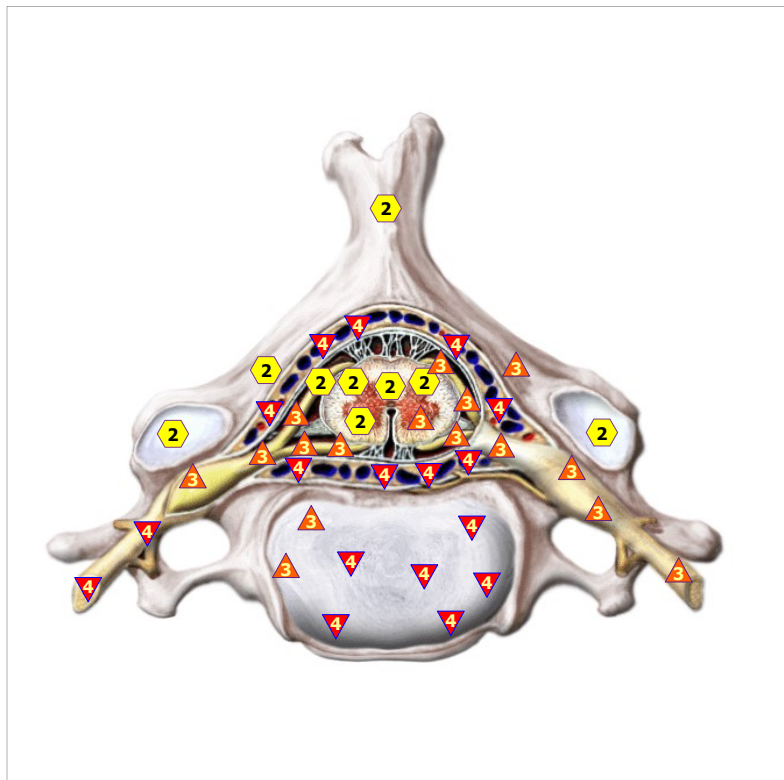
11/09/2024 SECOND NECK-BONE



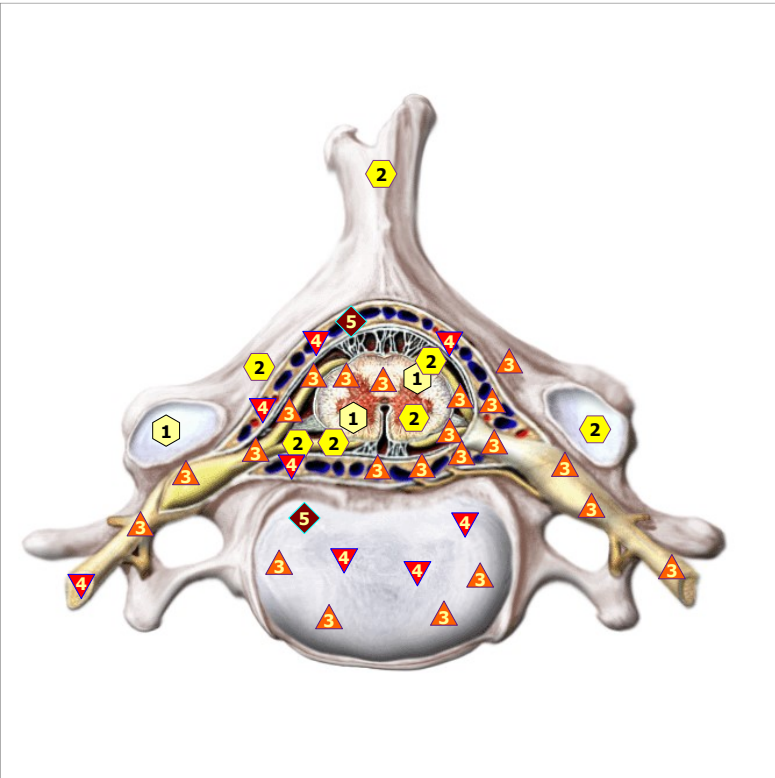
11/09/2024 THIRD NECK-BONE



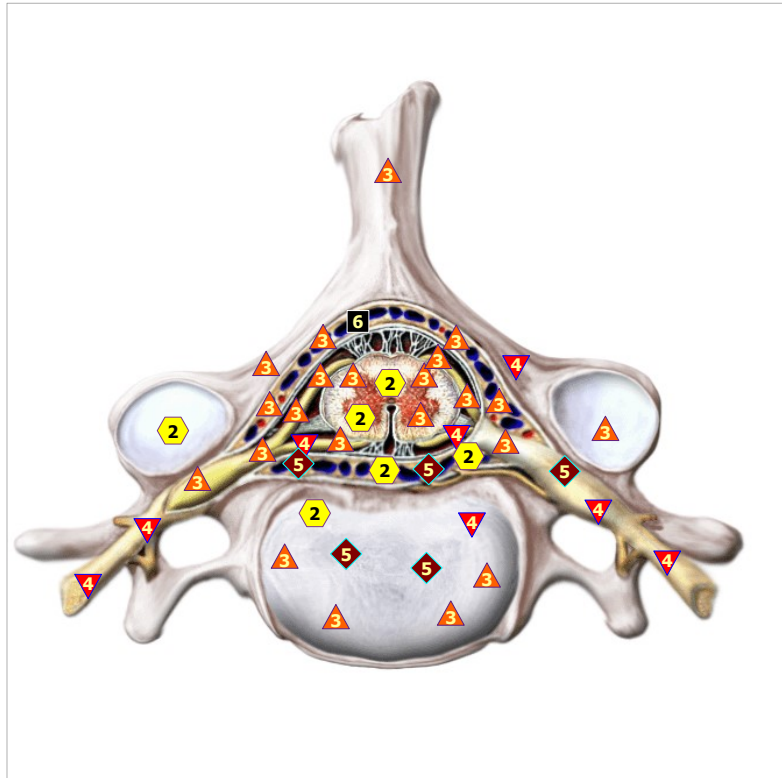
11/09/2024 FOURTH NECK-BONE



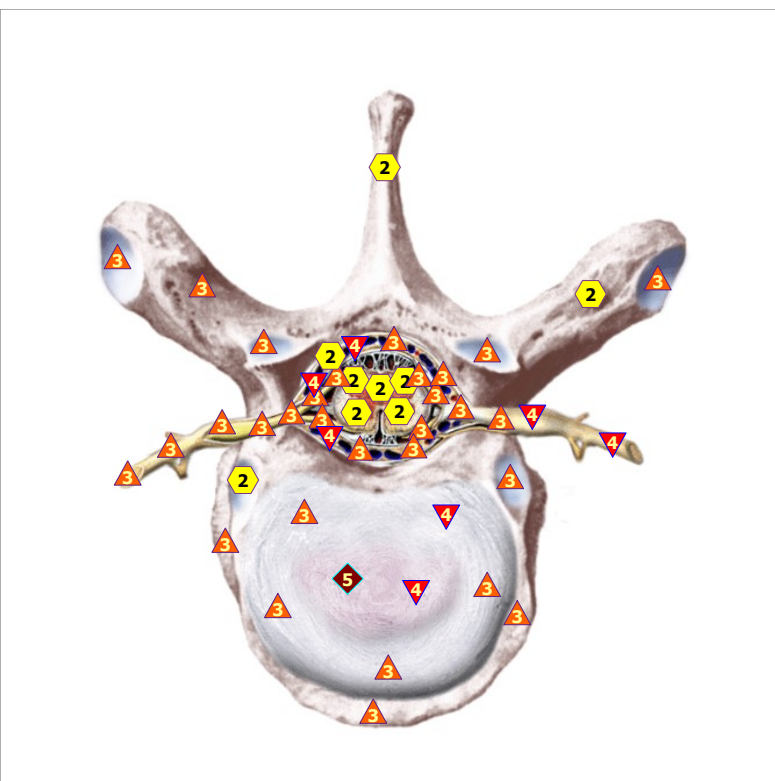
11/09/2024 FIFTH NECK-BONE



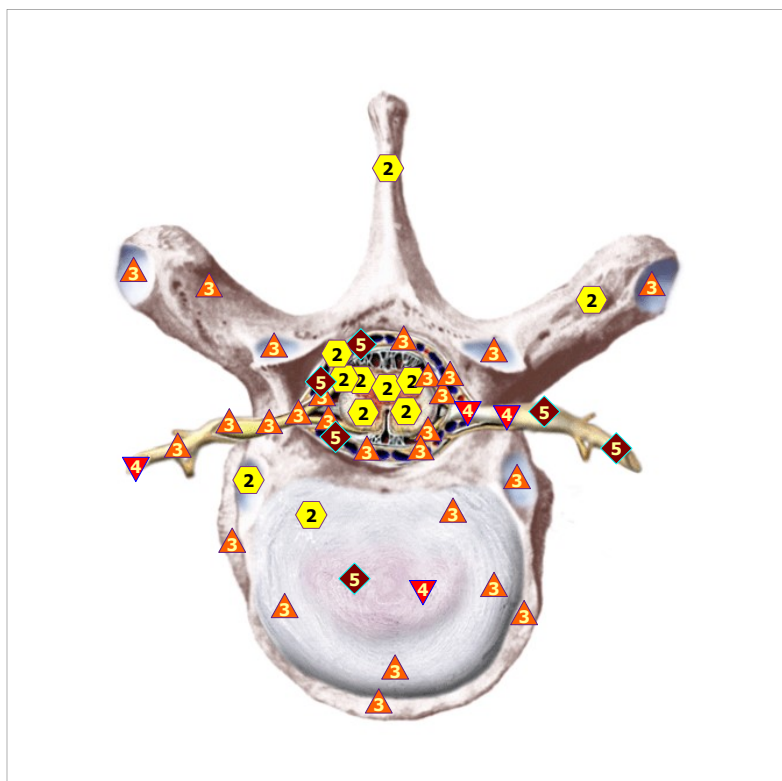
11/09/2024 SIXTH NECK-BONE



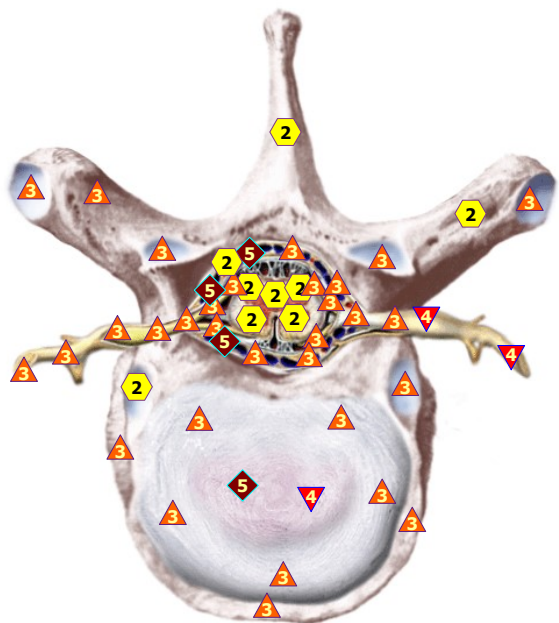
11/09/2024 SEVENTH NECK-BONE



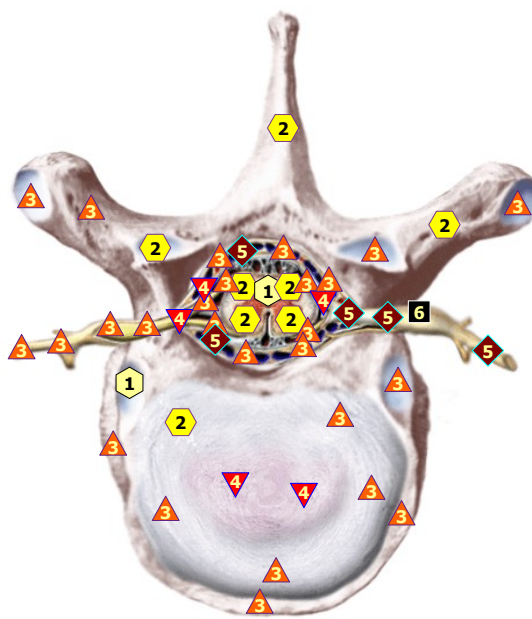
11/09/2024 FIRST THORACIC VERTEBRA



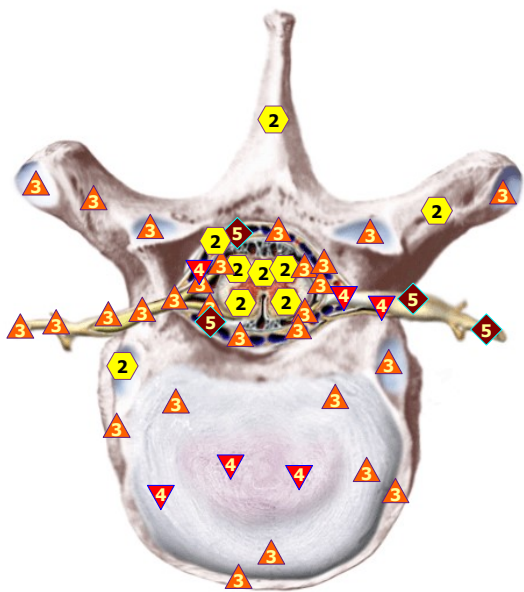
11/09/2024 SECOND THORACIC VERTEBRA



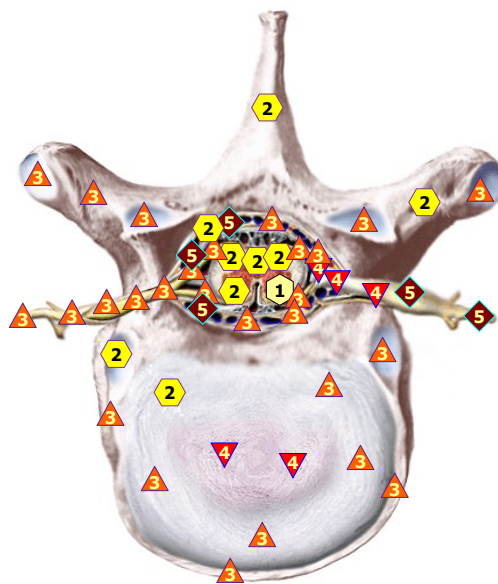
11/09/2024 THIRD THORACIC VERTEBRA



11/09/2024 FOURTH THORACIC VERTEBRA

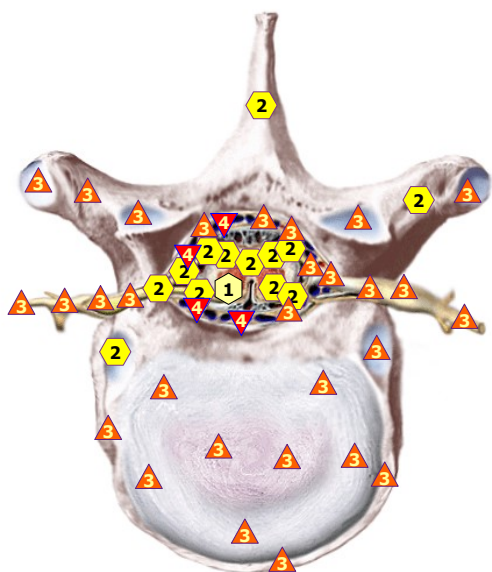


11/09/2024 FIFTH THORACIC VERTEBRA

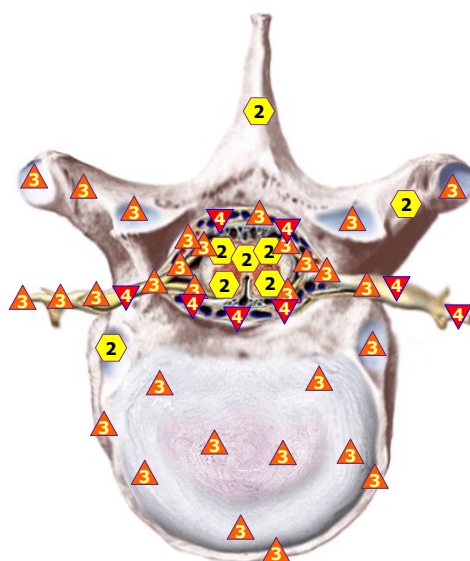


11/09/2024 SIXTH THORACIC VERTEBRA





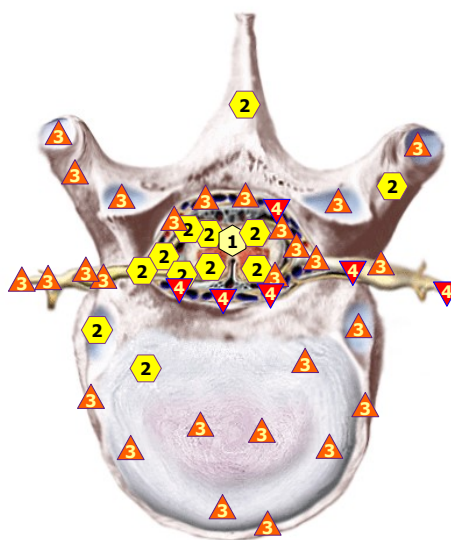
11/09/2024 SEVENTH THORACIC VERTEBRA



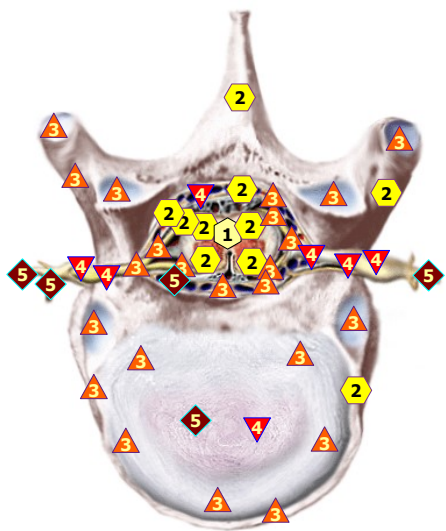
11/09/2024 EIGHTH THORACIC VERTEBRA



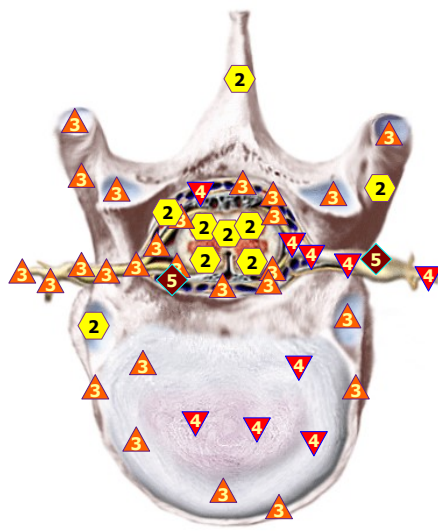
11/09/2024 NINTH THORACIC VERTEBRA



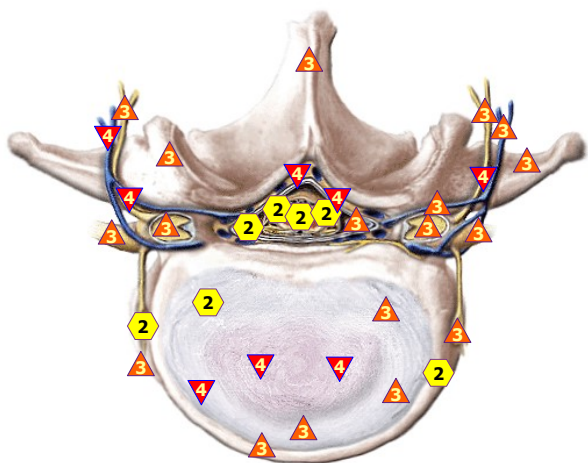
11/09/2024 TENTH THORACIC VERTEBRA



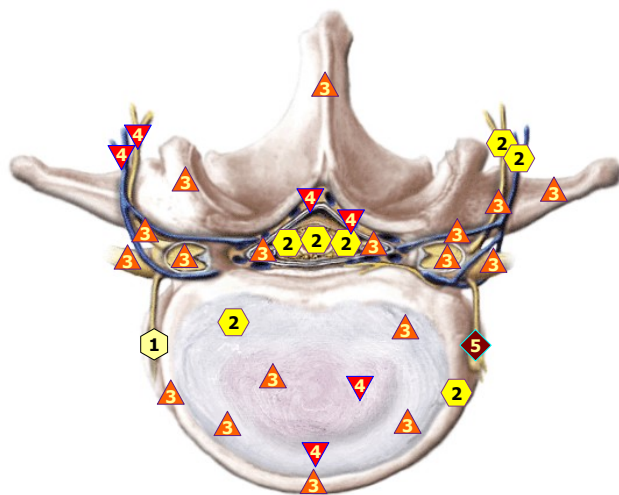
11/09/2024 ELEVENTH THORACIC VERTEBRA



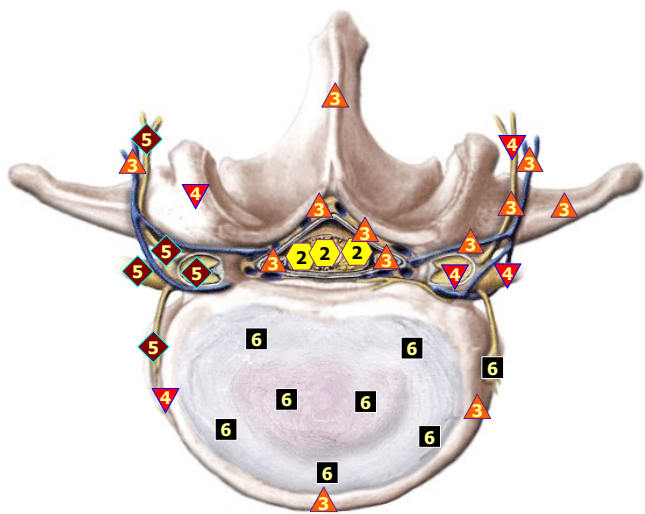
11/09/2024 TWELFTH THORACIC VERTEBRA



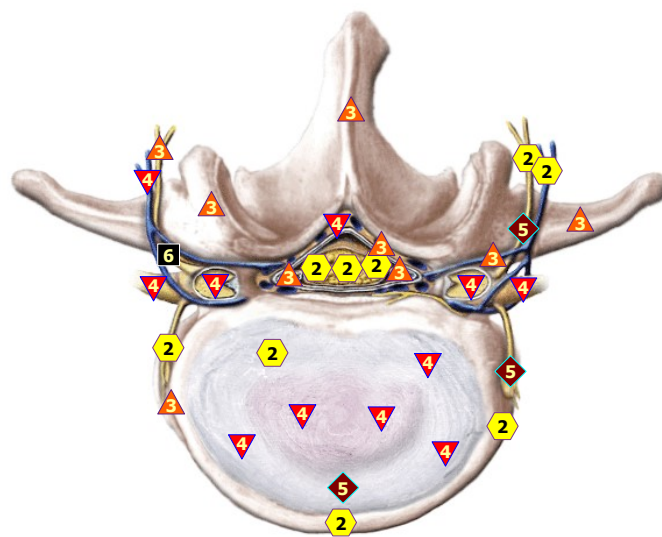
11/09/2024 FIRST LUMBAR VERTEBRA



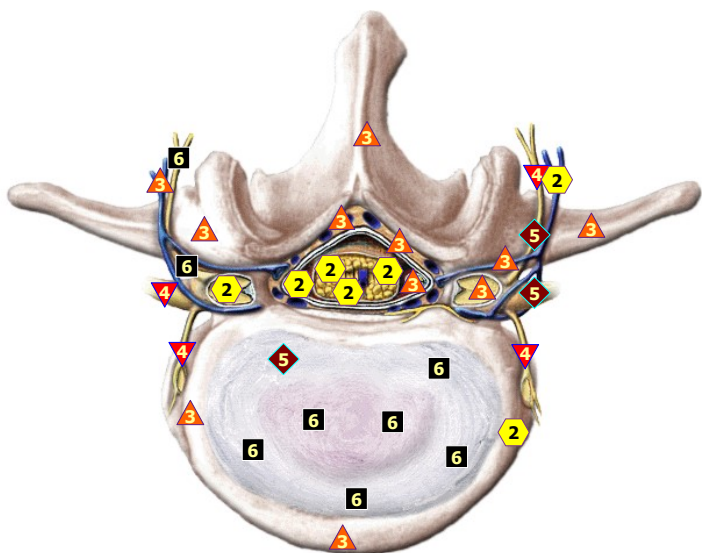
11/09/2024 SECOND LUMBAR VERTEBRA



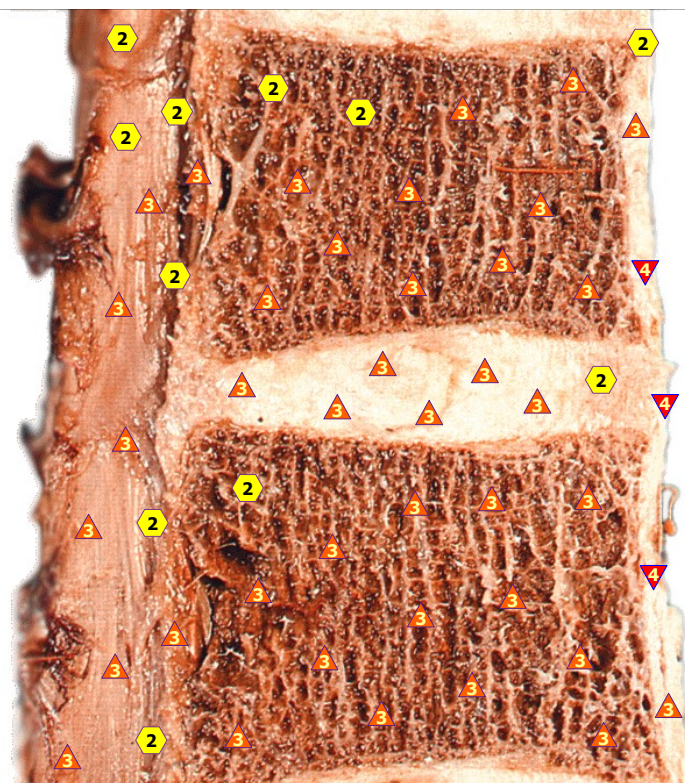
11/09/2024 THIRD LUMBAR VERTEBRA



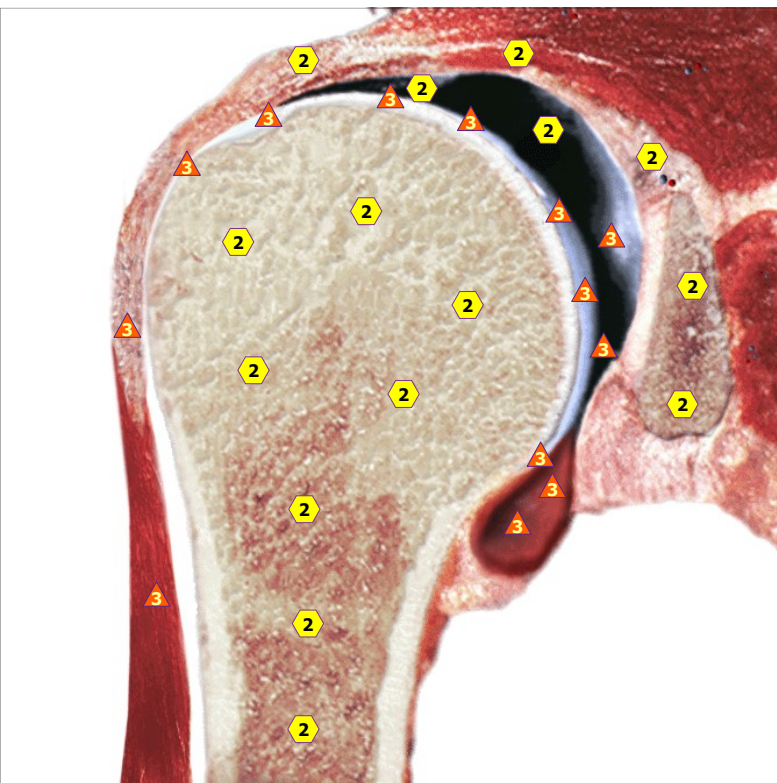
11/09/2024 FOURTH LUMBAR VERTEBRA



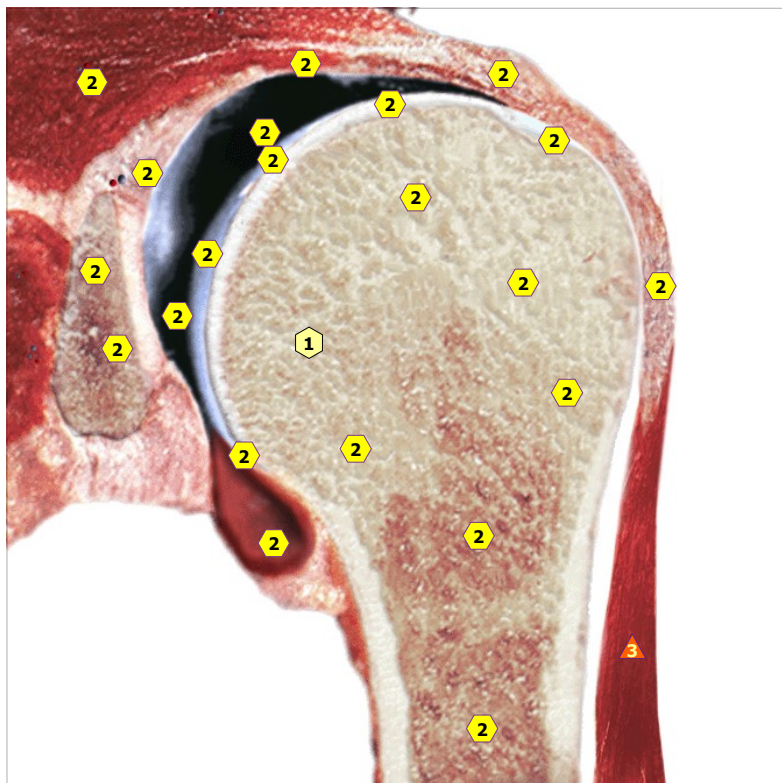
11/09/2024 FIFTH LUMBAR VERTEBRA



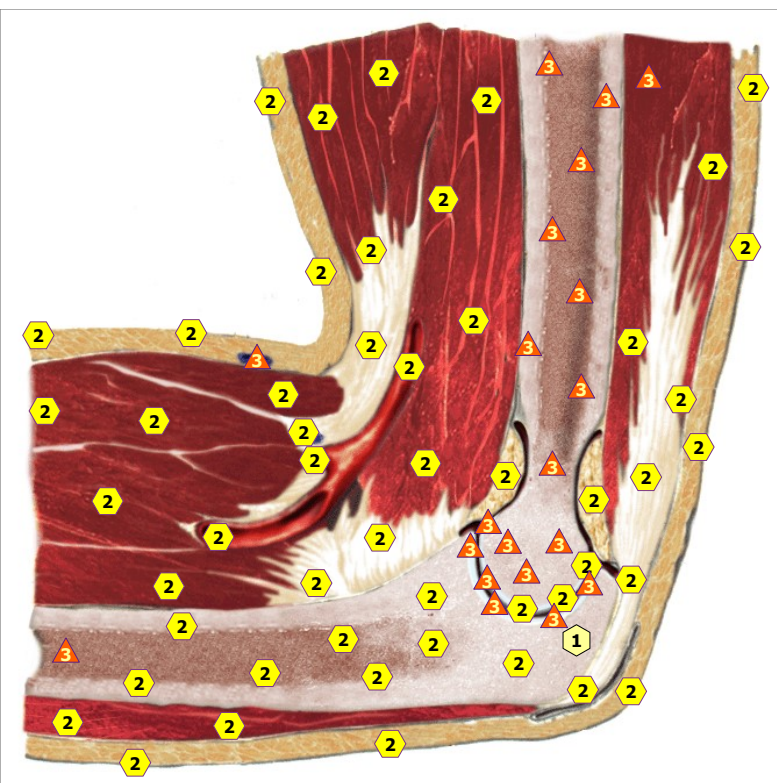
11/09/2024 MENA SAGITTAL INCISION OF THE VERTEBRAL BODY



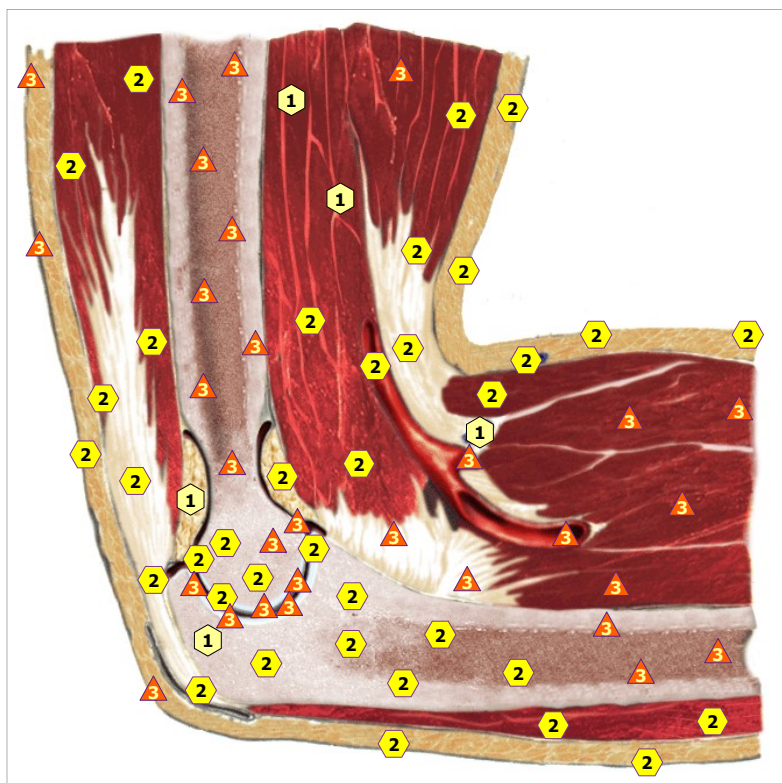
11/09/2024 SHOULDER JOINT; right



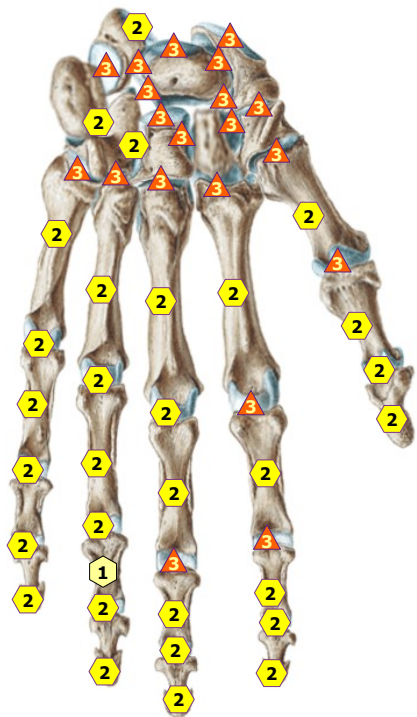
11/09/2024 SHOULDER JOINT; left



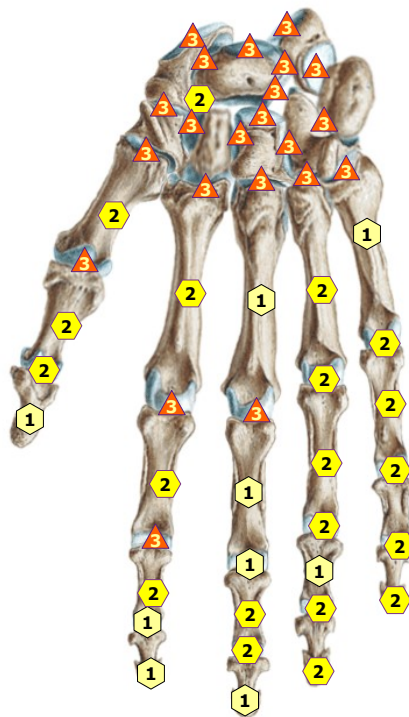
11/09/2024 ELBOW JOINT; right side view



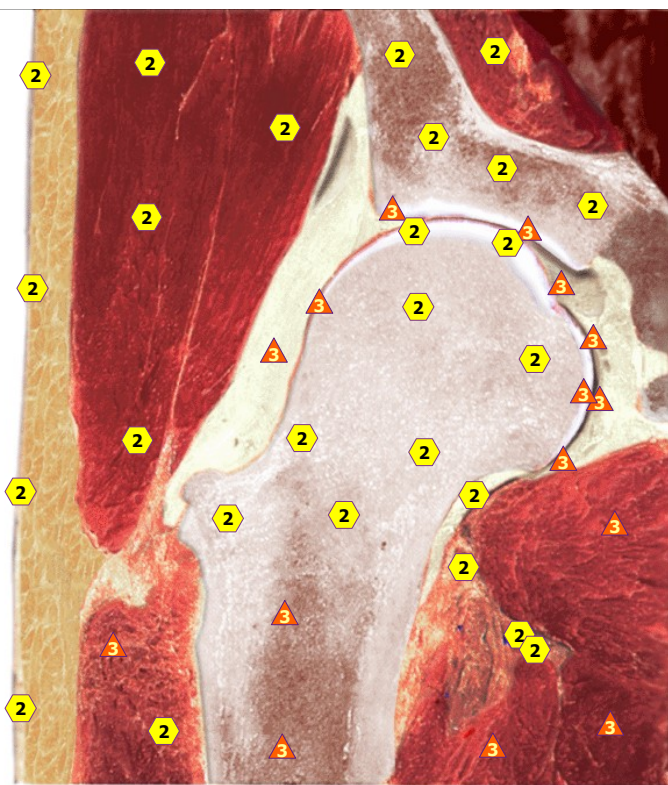
11/09/2024 ELBOW JOINT; left side view



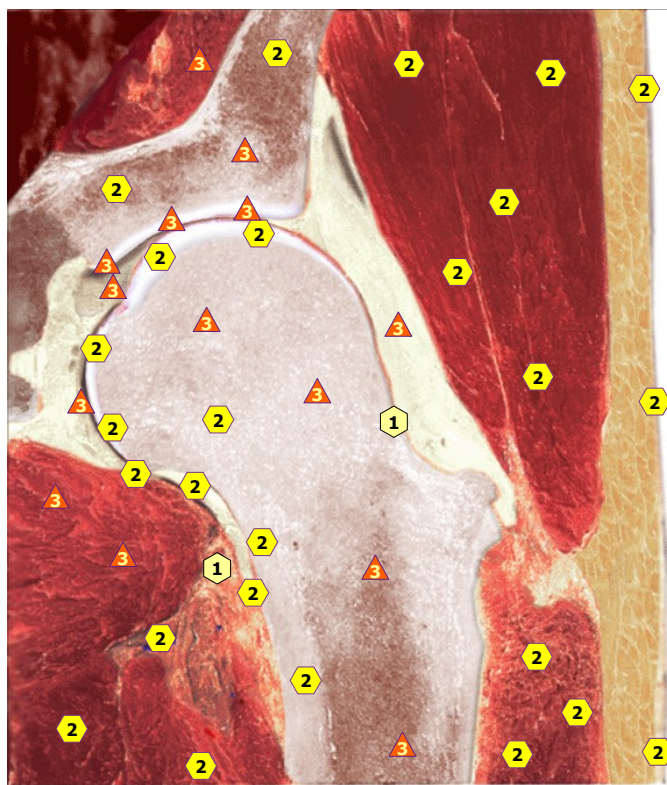
11/09/2024 Wrist, right



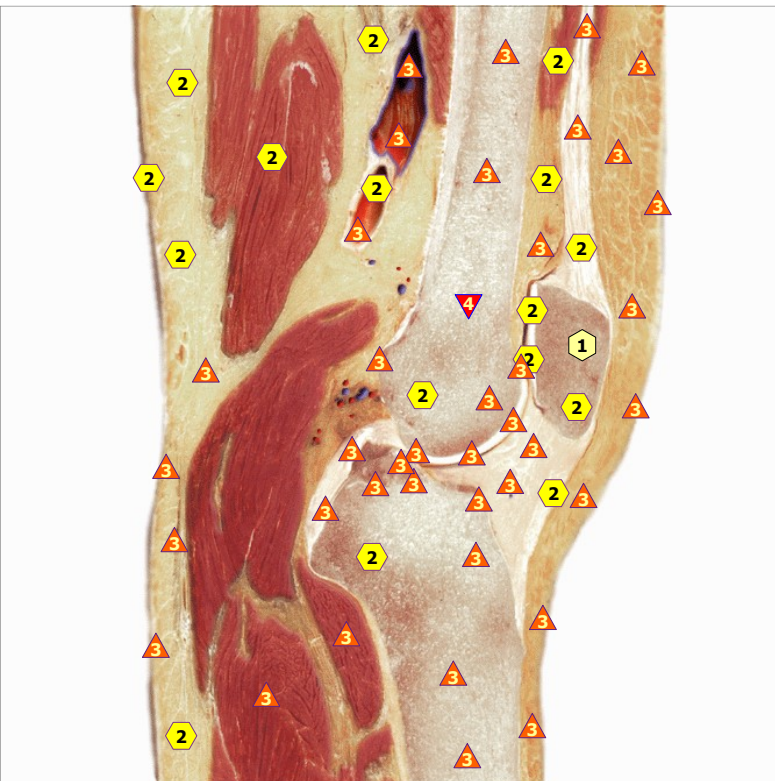
11/09/2024 Wrist, left



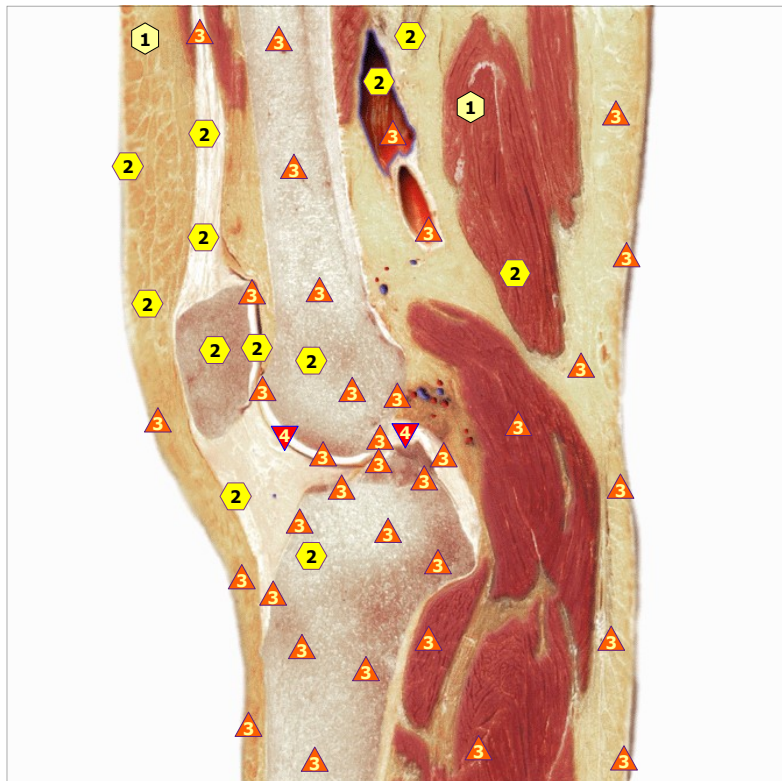
11/09/2024 HIP JOINT; right



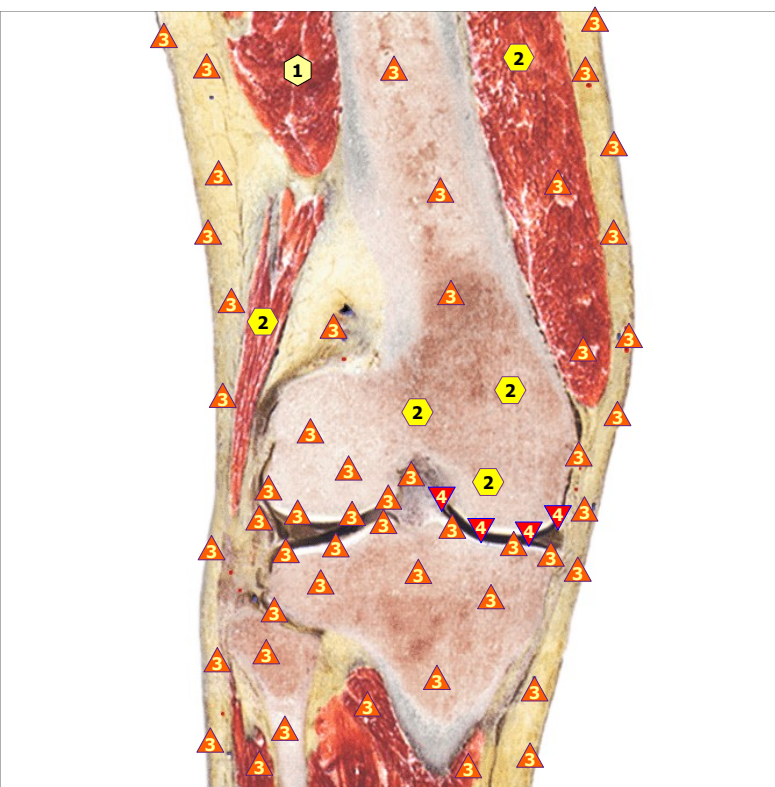
11/09/2024 HIP JOINT; left



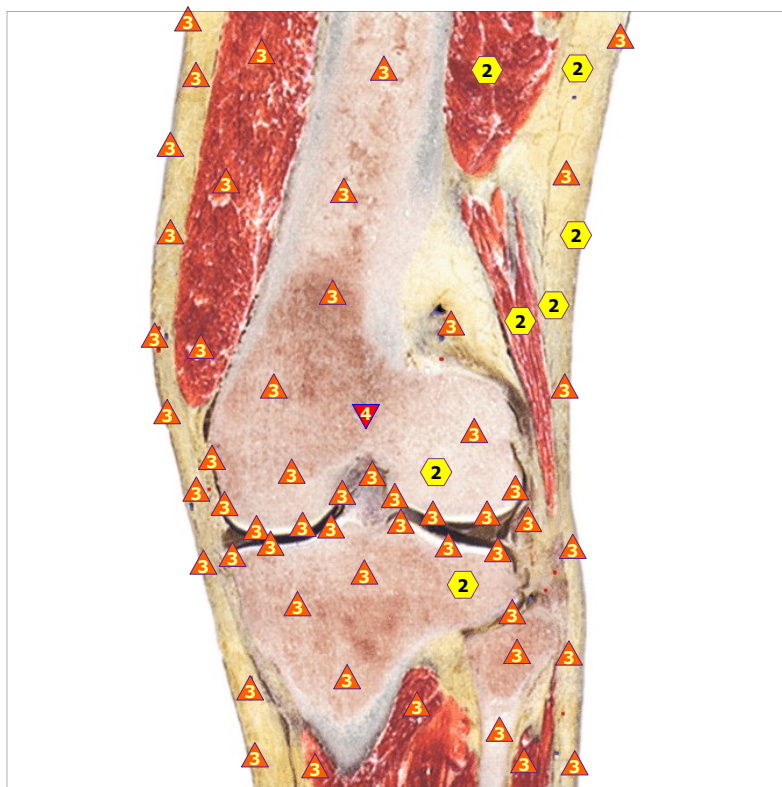
11/09/2024 KNEE JOINT; right from the side



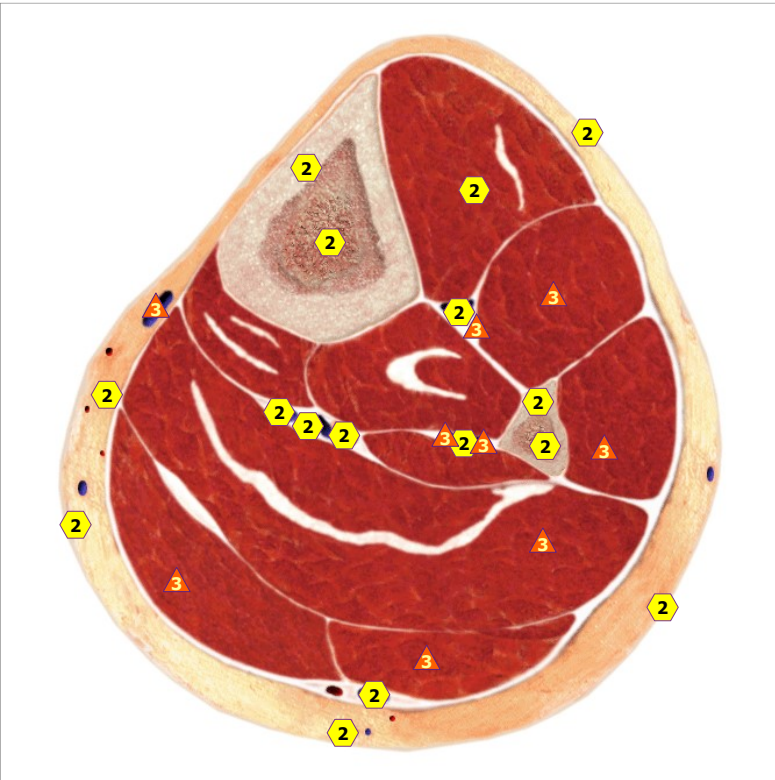
11/09/2024 KNEE JOINT; left from the side



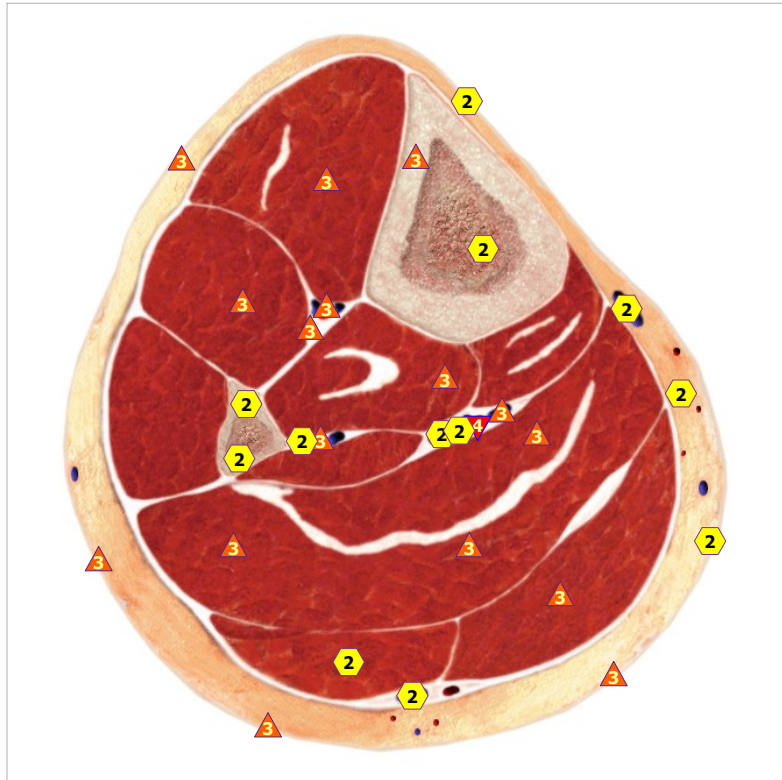
11/09/2024 The knee joint, the right front



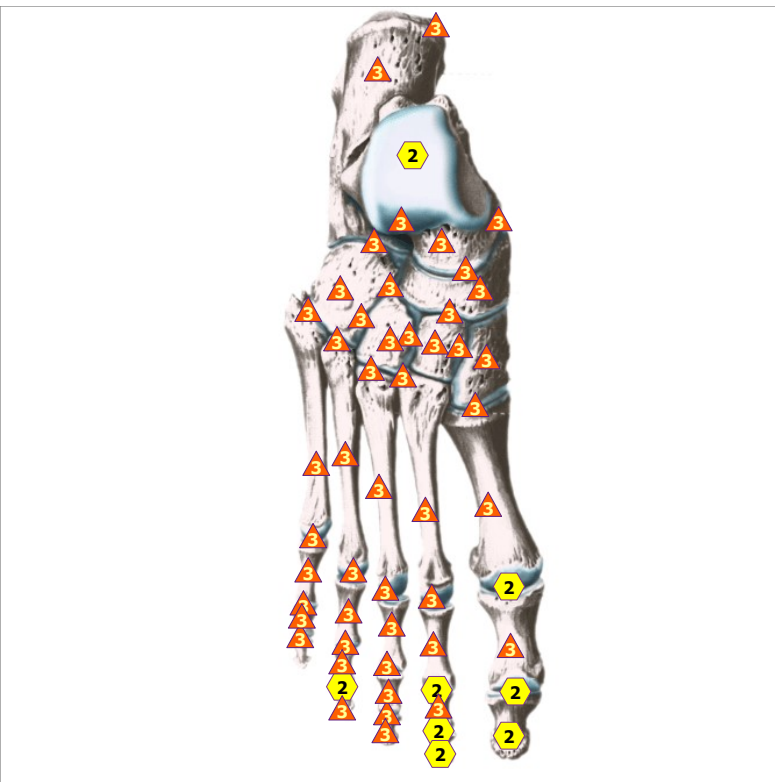
11/09/2024 Knee joint; left front



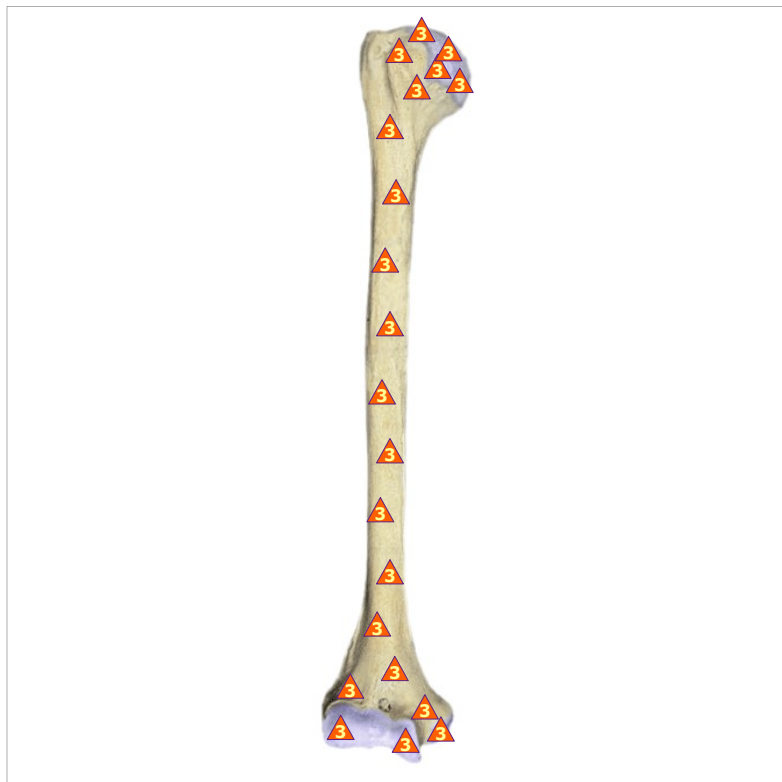11/09/2024 Transverse section of right shin



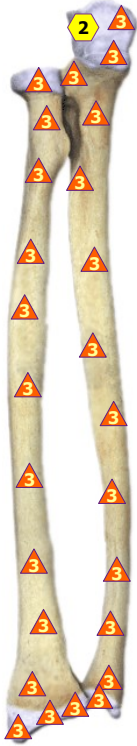11/09/2024 Transverse section left shin



11/09/2024 FOOT JOINT; right from above



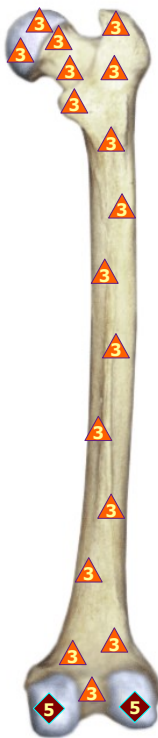
11/09/2024 BONE OF UPPER ARM; on the right



11/09/2024 FOREARM BONES; from the right



11/09/2024 FOREARM BONES; from the left




11/09/2024 FEMUR; right

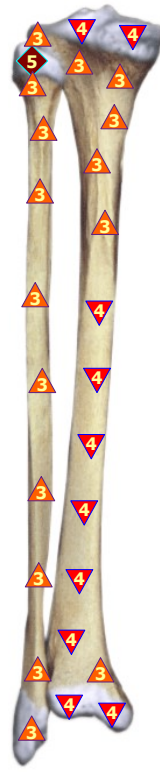


11/09/2024 FEMUR; left

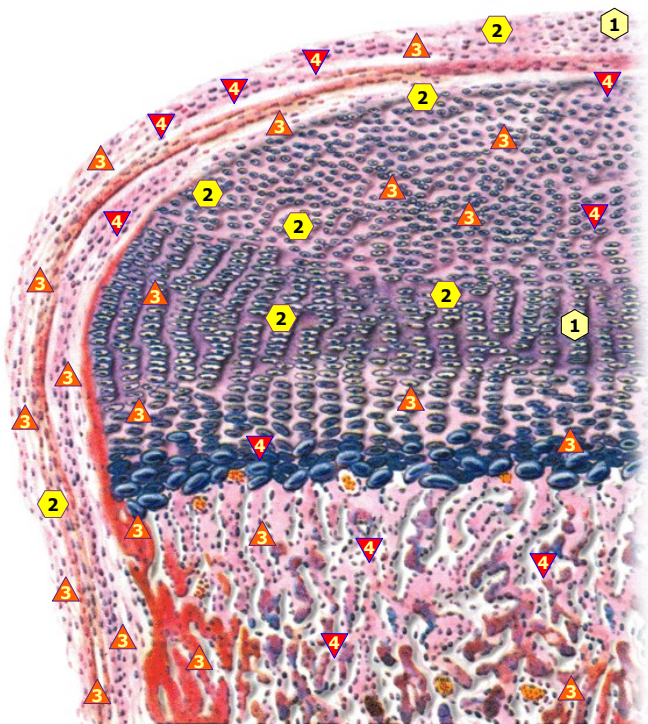




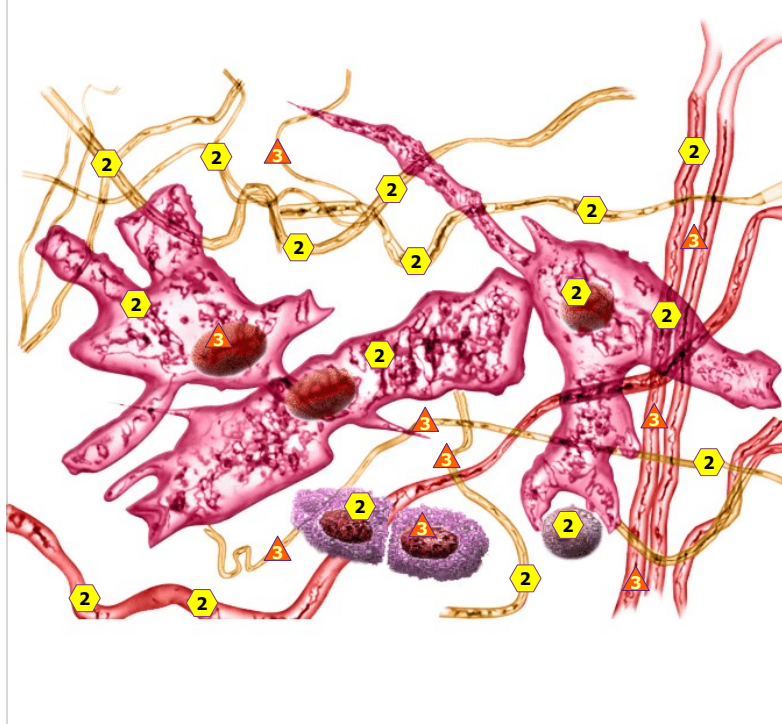
11/09/2024 SHIN BONES; right



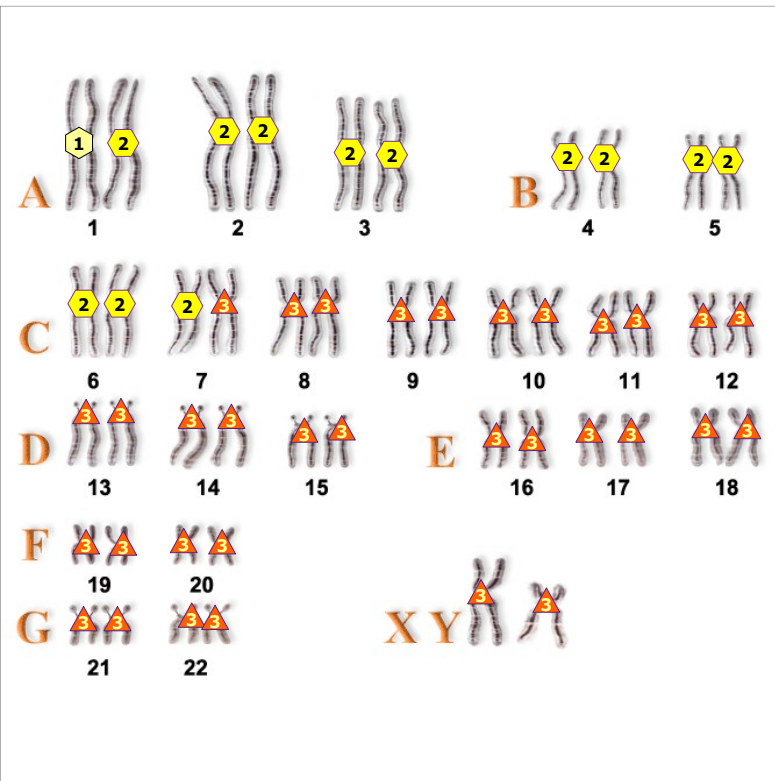
11/09/2024 SHIN BONES; left



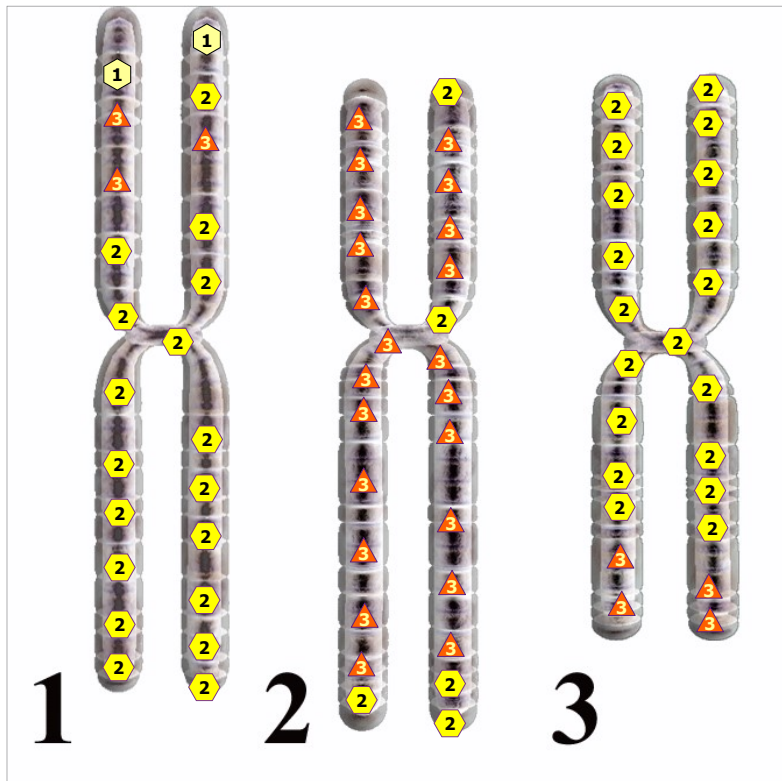
11/09/2024 JOINT SURFACE



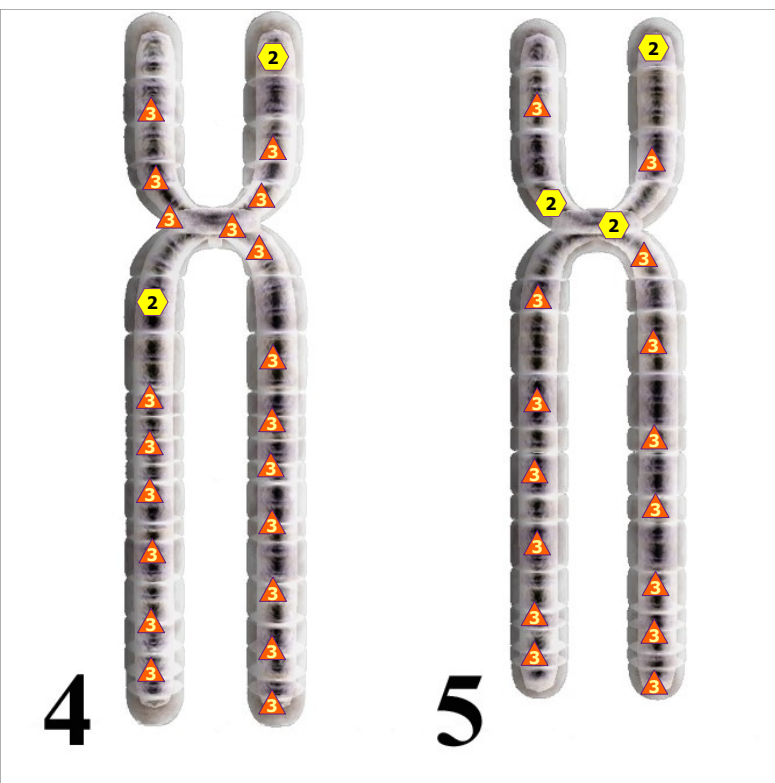
11/09/2024 CONNECTIVE TISSUE



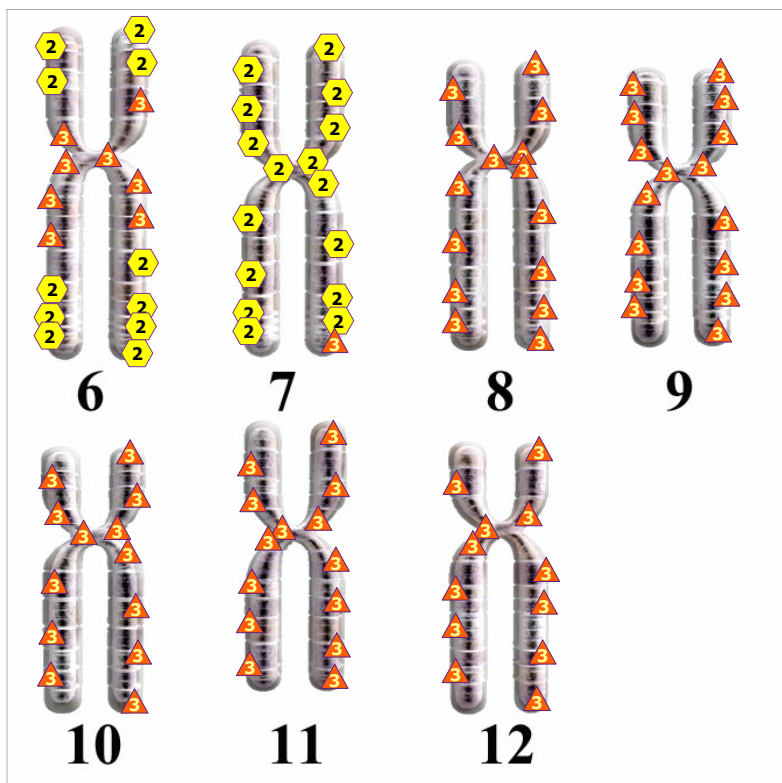
11/09/2024 SET OF MALE CHROMOSOMES.



11/09/2024 Chromosome gr. A



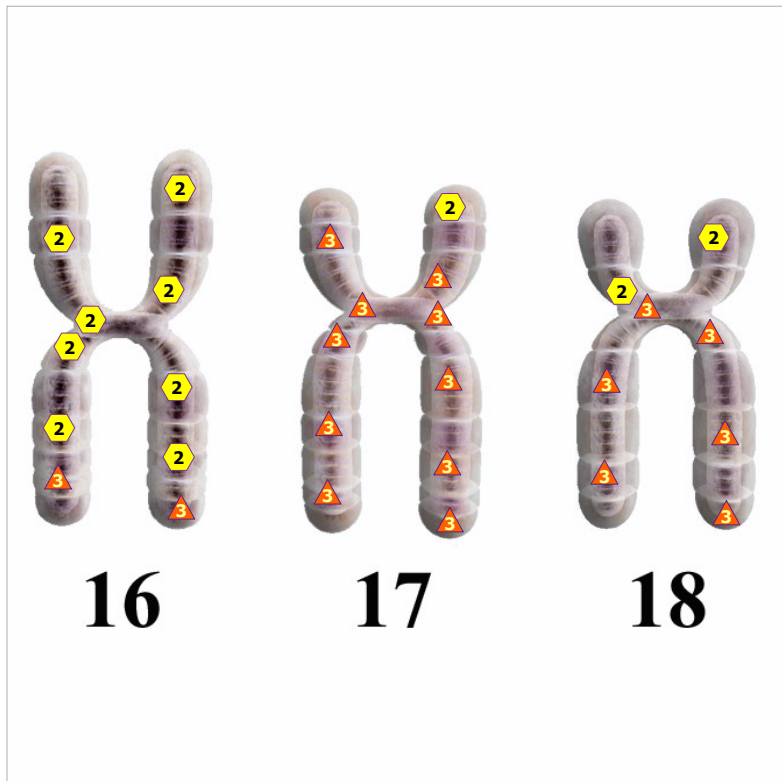
11/09/2024 Chromosome gr. B



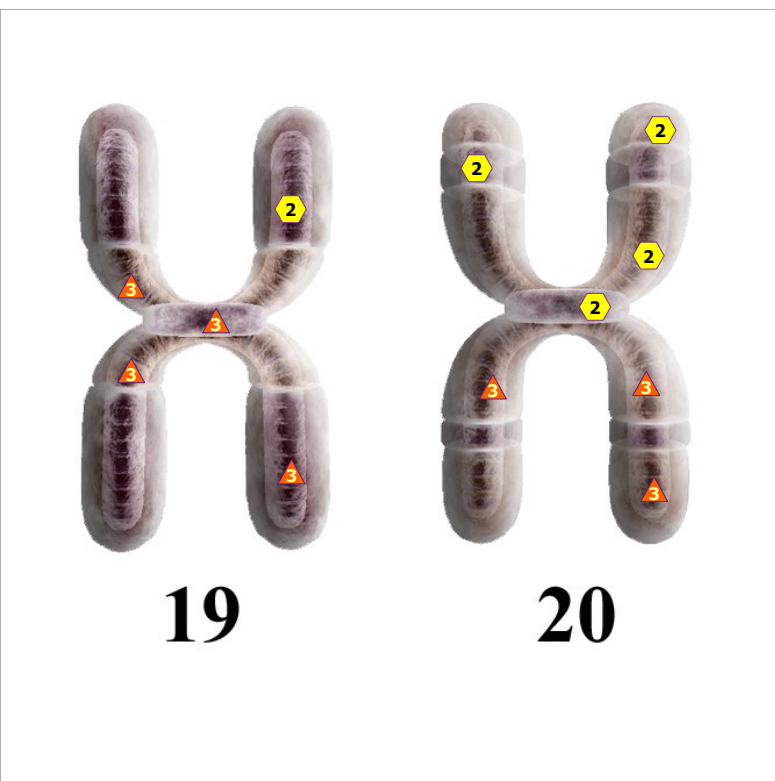
11/09/2024 Chromosome gr. C



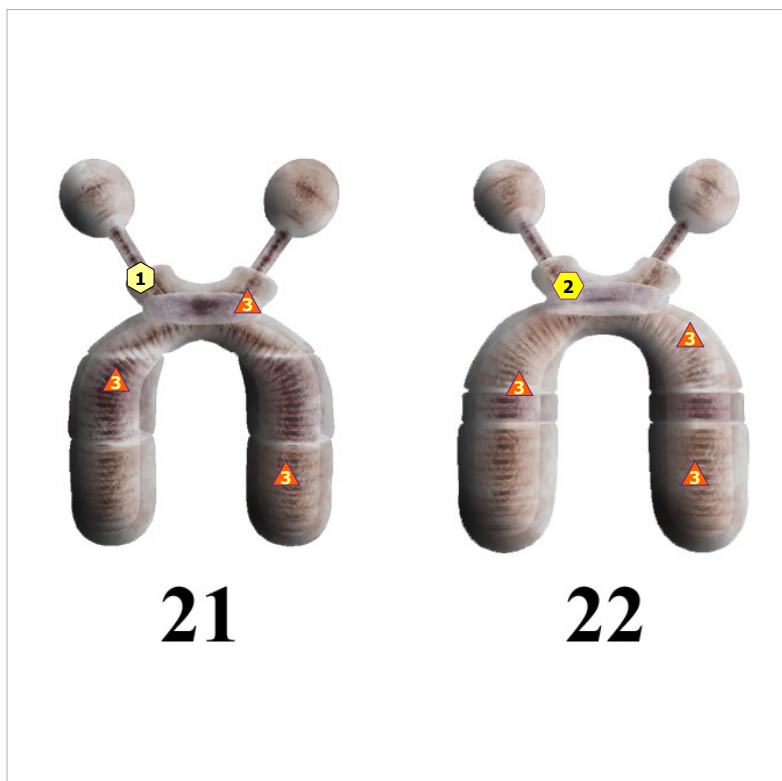
11/09/2024 CHROMOSOMES gr. D



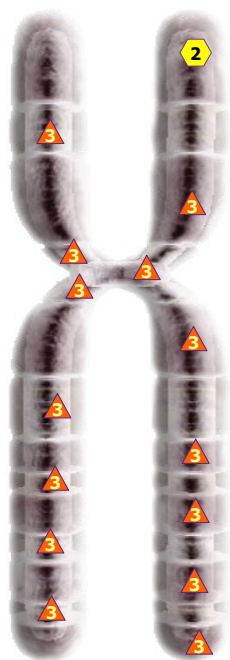11/09/2024 Chromosome gr. E



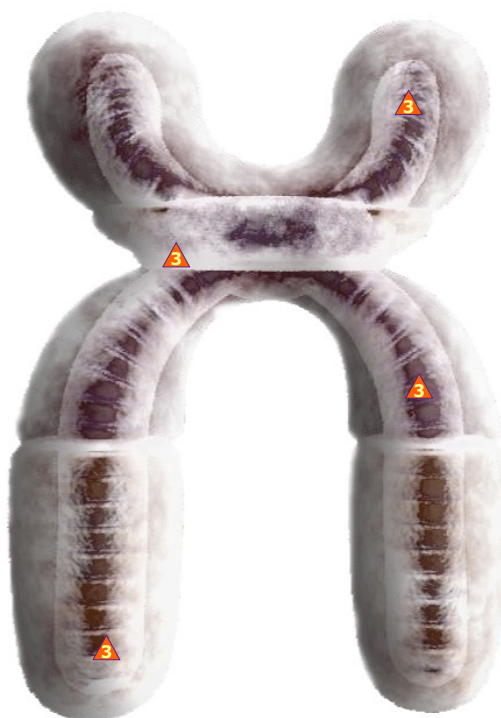11/09/2024 CHROMOSOMES gr.F



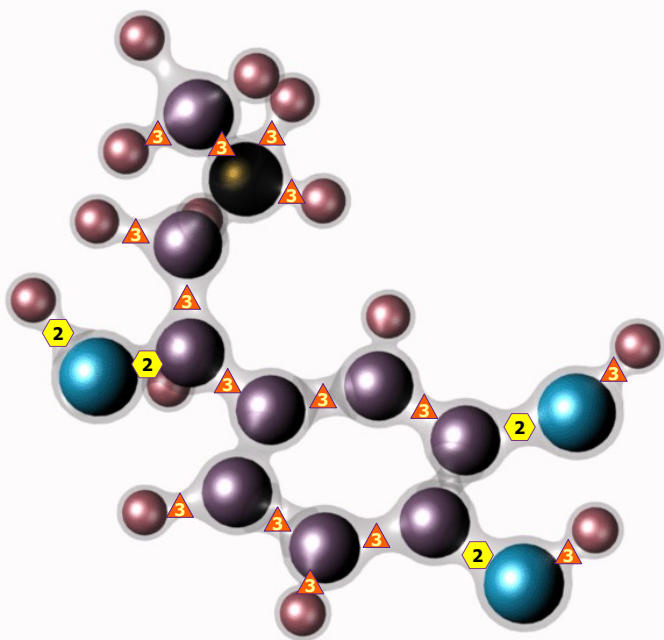
11/09/2024 CHROMOSOMES gr.G



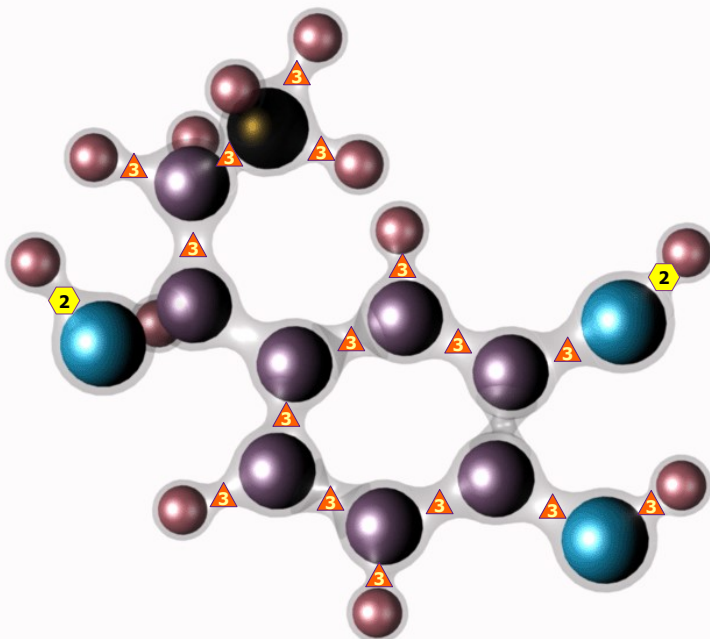
11/09/2024 X - CHROMOSOME



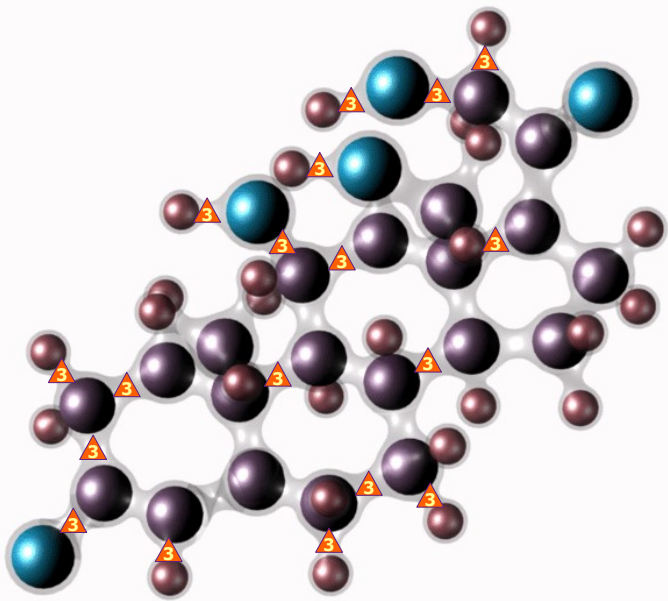
11/09/2024 Y - CHROMOSOME



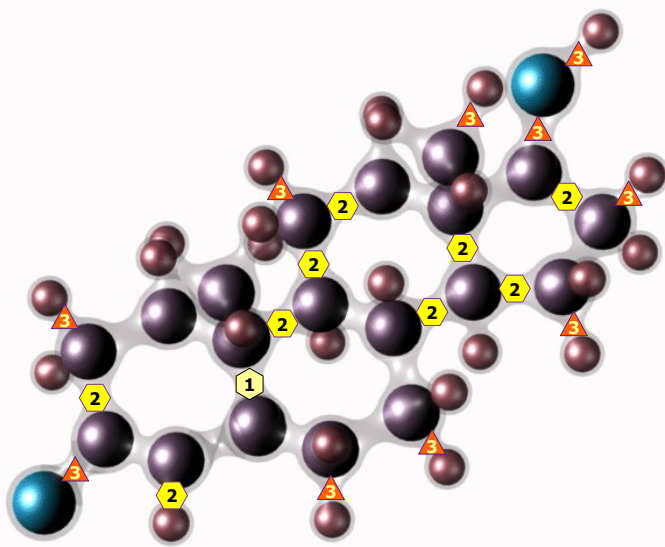
11/09/2024 ADRENALIN



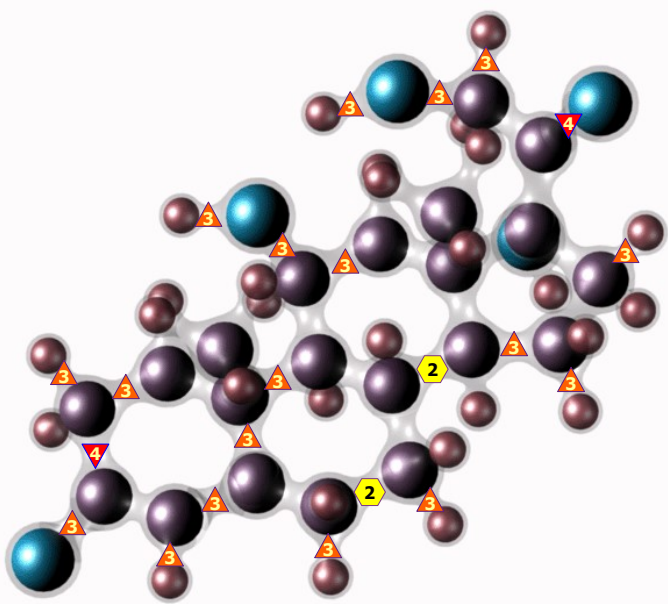
11/09/2024 NORADRENALINUM



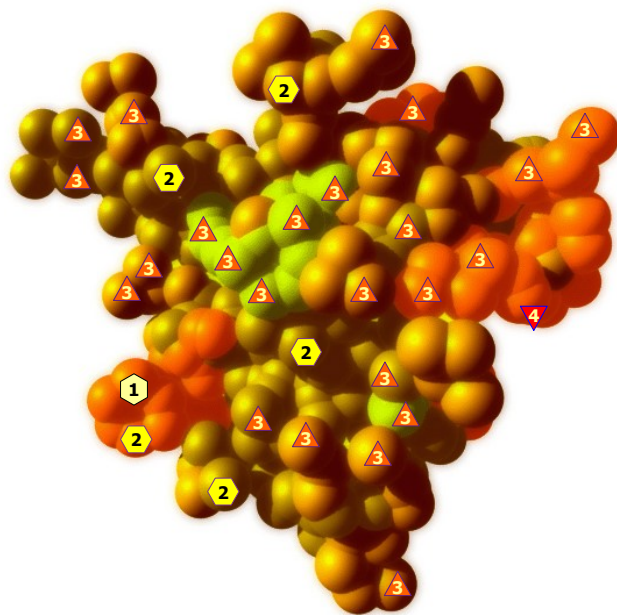
11/09/2024 ALDOSTERONUM




11/09/2024 TESTOSTERONE



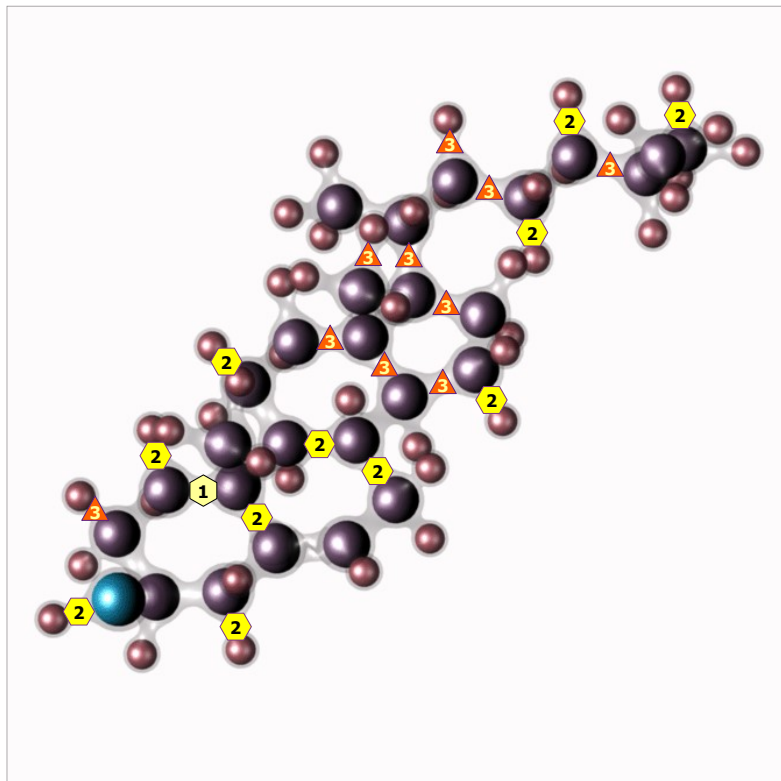
11/09/2024 CORTISOL




11/09/2024 INSULIN



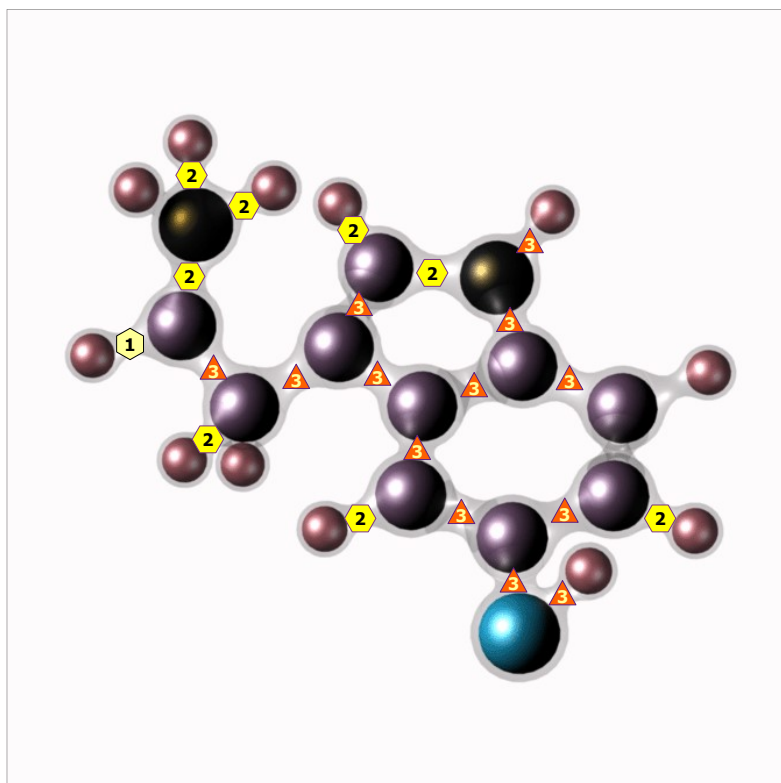
11/09/2024 GLYCOGEN



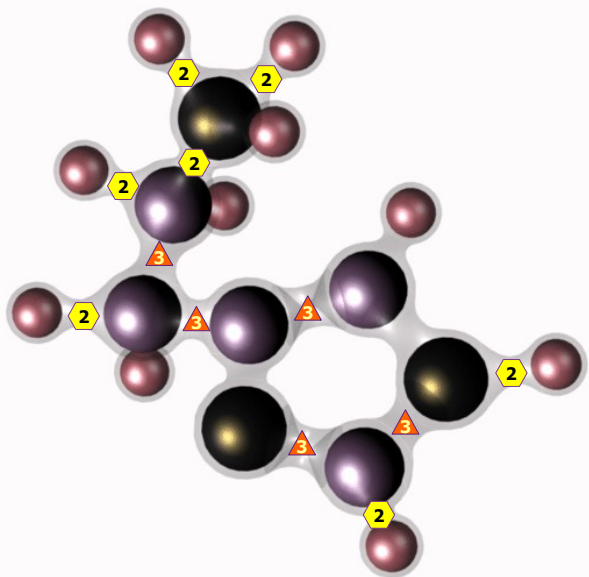
11/09/2024 CHOLESTERIN



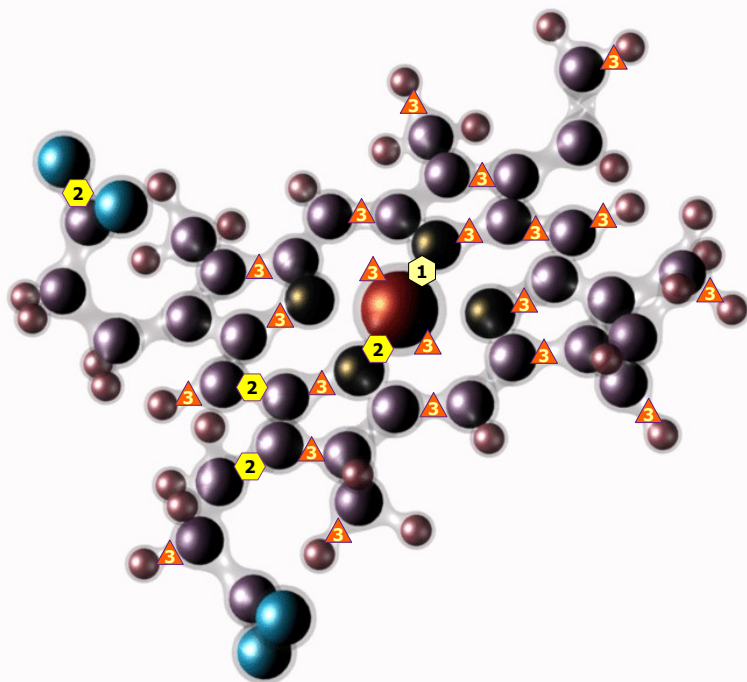
11/09/2024 HEPARINUM



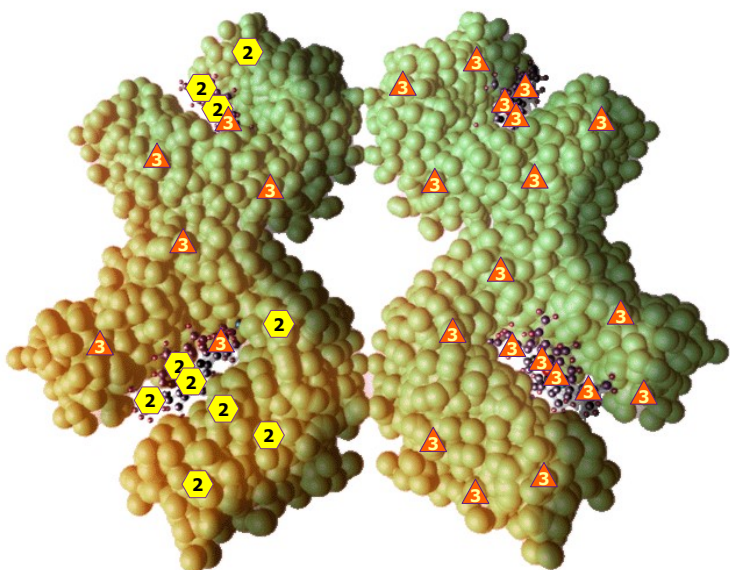
11/09/2024 SEROTONIN



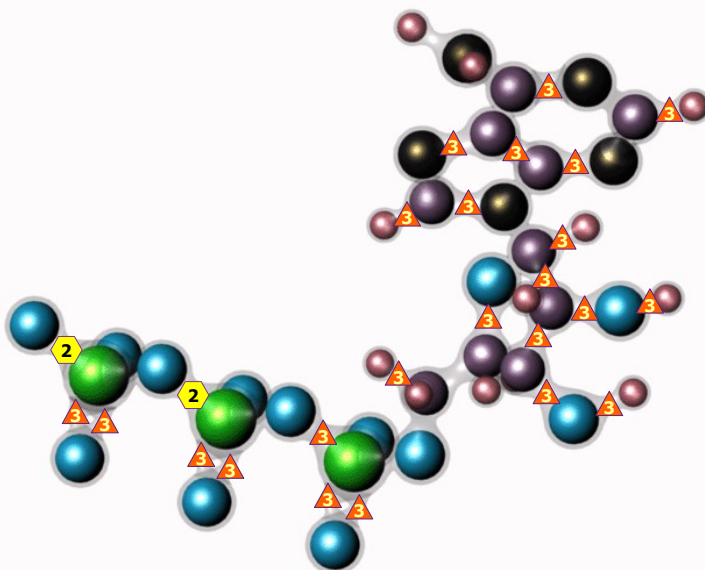
11/09/2024 HISTAMINE



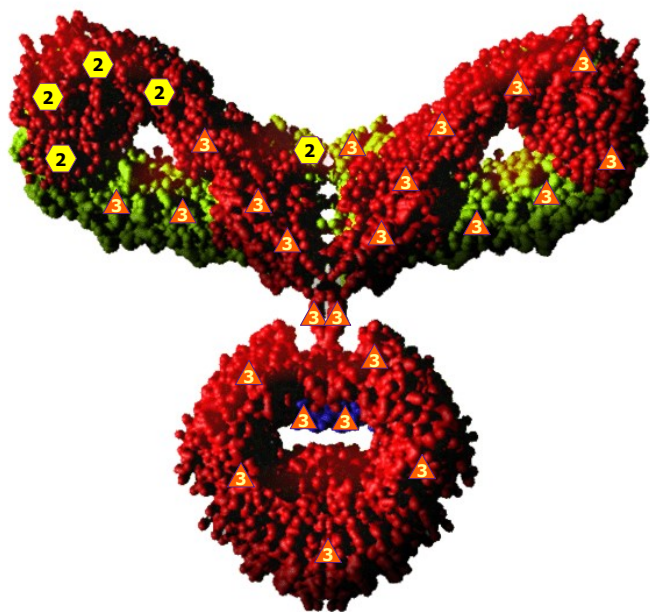
11/09/2024 HEME




11/09/2024 HAEMOGLOBIN



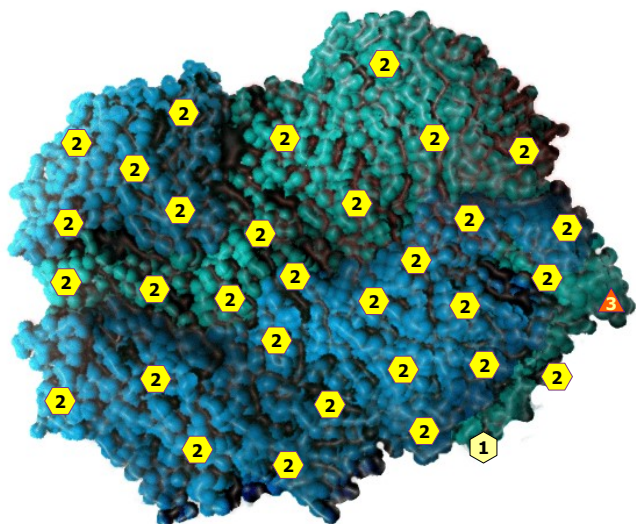
11/09/2024 ATP



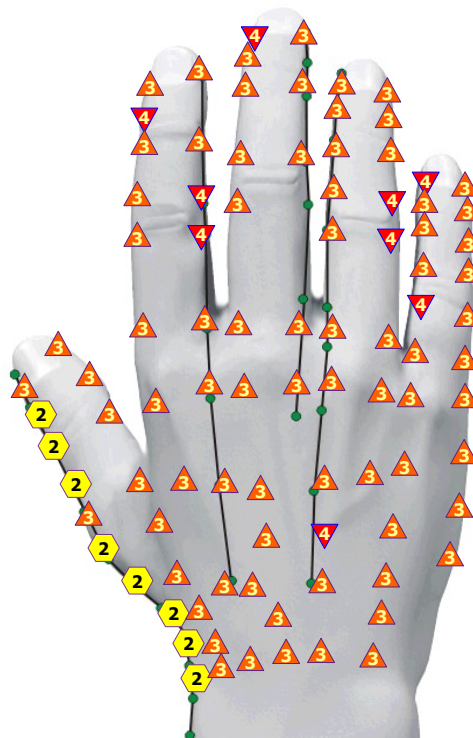
11/09/2024 IMMUNOGLOBULIN E



11/09/2024 ALCOHOL DEHYDROGENASE

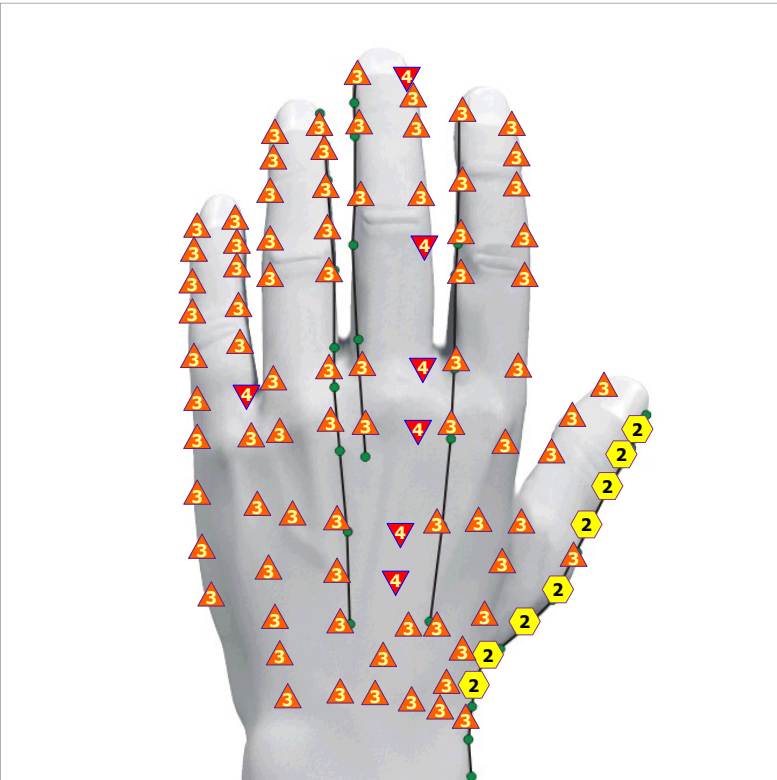


11/09/2024 LACTATE DEHYDROGENASE

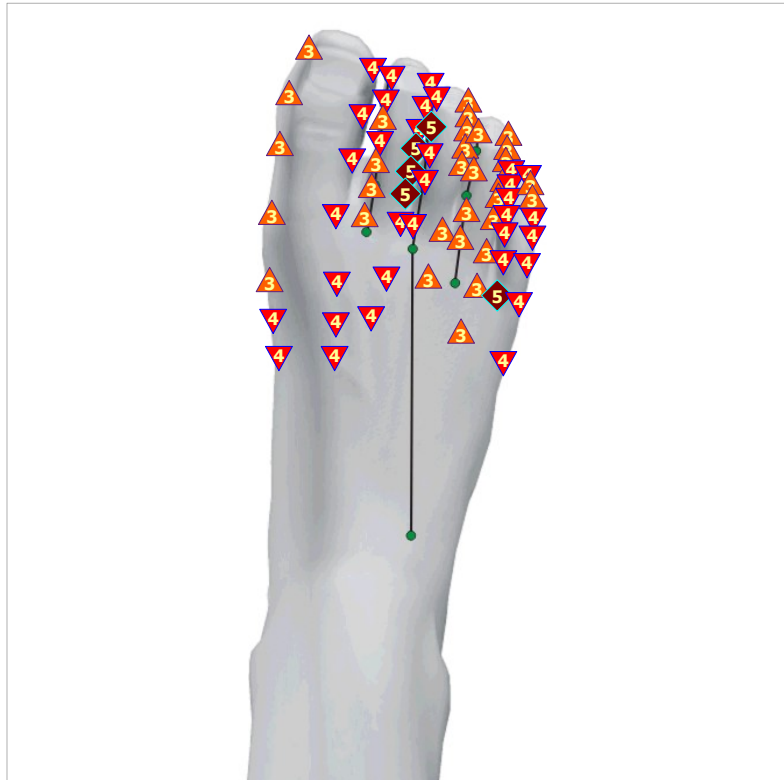

11/09/2024 ACUPUNCTURE POINTS BY FOLLE ON THE RIGHT WRIST

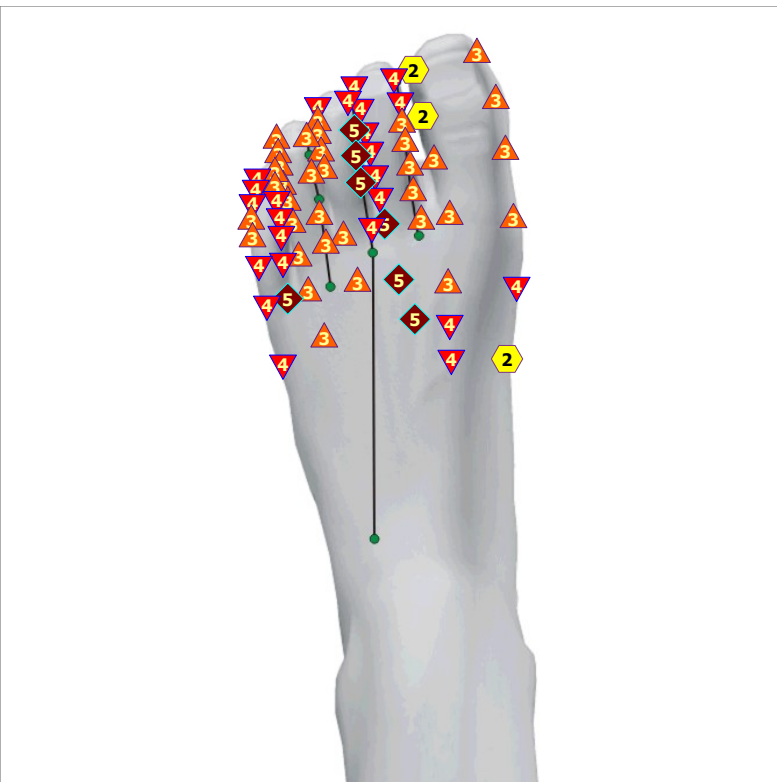



11/09/2024 ACUPUNCTURE POINTS BY FOLLE ON THE LEFT WRIST



11/09/2024 ACUPUNCTURE POINTS BY FOLLE ON THE RIGHT FOOT



11/09/2024 ACUPUNCTURE POINTS BY FOLLE ON THE LEFT FOOT